

Acute Mastoiditis Complicated With Subperiosteal Abscess in Children: Report of Two Cases

Yu-Chien Chang, Fuh-Cherng Jeng, Chia-Der Lin, Ming-Hsui Tsai

Department of Otolaryngology, China Medical College Hospital,
Taichung, Taiwan, R.O.C.

Since the introduction of antibiotics, the incidence of otitis media induced complications such as mastoiditis and subperiosteal abscess has significantly decreased. We experienced two cases. The first case is a four-year-old boy who underwent right simple mastoidectomy and myringotomy with tympanic tube insertion. During the operation, we found a lot of pus accumulated in the subperiosteal space, mastoid cavity and middle ear. Tenacious secretions and edematous mucosa blocked the aditus ad antrum. The second case is a thirteen-year-old boy who underwent modified radical mastoidectomy and type III tympanoplasty. A great amount of thick, yellowish discharge was removed from the subcutaneous tissue, subperiosteal space and mastoid cavity. The mastoid cavity and the middle ear were filled with a huge cholesteatoma which blocked the aditus ad antrum. Both patients were treated with intravenous antibiotics during hospitalization. They recovered well after their operations and had no evidence of recurrence over 13 and 5 months of follow-up, respectively. (*Mid Taiwan J Med* 2001;6:179-84)

Key words

mastoiditis, subperiosteal abscess

INTRODUCTION

Otitis media is a common childhood disease [1]. In the modern era, due to the usage of antibiotics, the number of otitis media related complications, such as acute mastoiditis and subperiosteal abscess, has declined. We recently treated two patients with acute mastoiditis complicated with subperiosteal abscess; one case was due to acute otitis media and the other was from cholesteatoma. We have reported here the clinical presentations, operation findings and treatments. We also reviewed the literature and discussed the disease's pathogenesis.

CASE REPORT

Case one was a four-year-old boy without remarkable past history, who suffered from fever and right otalgia at the end of April 2000. Right otitis media was diagnosed at a local medical center and oral antibiotics were prescribed. However, fever persisted for eight days in spite of the usage of oral antibiotics, and he was referred to our hospital. Physical examination revealed a mildly injected right tympanic membrane and a 2 cm × 2 cm painful swollen mass over the right mastoid area. No facial paralysis was found. Tympanogram showed type B in the right ear. His white blood cell count was 37,850/ul, including 81.5% neutrophils. The patient's condition was diagnosed as acute otitis media complicated with acute mastoiditis, and he was admitted for intravenous

Received : June 21, 2001.

Revised : August 10, 2001.

Accepted : August 13, 2001.

Address reprint requests to : Yu-Chien Chang, Department of Otolaryngology, China Medical College Hospital, No 2, Yuh-Der Road, Taichung 404, Taiwan, R.O.C.

antibiotic treatment (augmentin 400 mg per 8 hours). A mastoid CT scan revealed cloudiness over the right mastoid sinus. The patient underwent a right simple mastoidectomy and tympanotomy with insertion of a ventilation tube. We found a great amount of tenacious pus in the middle ear, the mastoid cavity, and the subperiosteal space. Tenacious secretions and edematous mucosa blocked the aditus ad antrum. Fever subsided after surgery and he was discharged on the seventh day of hospitalization. A bacterial culture revealed streptococcus pneumonia sensitive to amoxicillin. He recovered well without recurrence after thirteen months' of following-up.

Case two was a thirteen-year-old boy with a personal history of G6PD deficiency. He came to our hospital complaining of a painful swollen mass over his left post-auricular area on January 1, 2001. According to his father's statement, this boy had been visiting the local medical center for the post-auricular painful swollen mass since November 2000. The symptoms relapsed several times and oral antibiotics treatment was intermittent. He presented with no fever and no facial paralysis. Physical examination revealed a 3 cm × 3 cm painful swollen mass with fluctuation over the left mastoid area (Fig. 1). An aural polyp and purulent discharge were also noted in the ear canal. Pure tone audiometry showed 40 dB conductive hearing loss with a 30 dB air-bone gap in the left ear.

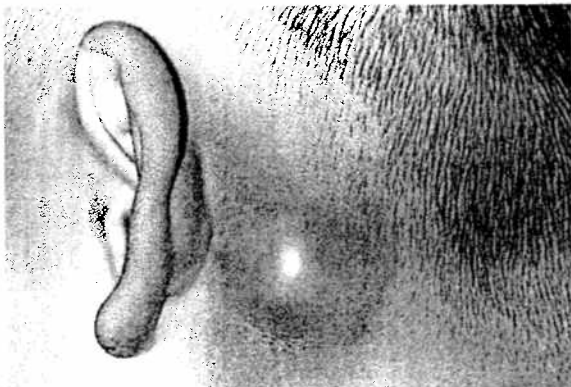


Fig. 1 A 3 cm × 3 cm painful swollen mass with fluctuation over the left mastoid area.

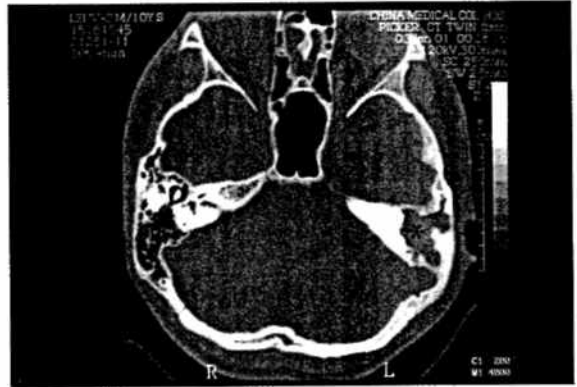


Fig. 2 Mastoid CT scan showed extensive destruction of bony septa of the mastoid cavity, forming a coalescent mastoiditis. Soft tissue infiltration over the middle ear cavity and external auditory canal were also noted.

Tympanogram revealed type B in the left ear and type A in the right ear. White blood cell count with differential count was within normal limits. A mastoid CT scan of the left mastoid sinus disclosed a broken bony septa in the left mastoid sinus, referred to as coalescent mastoiditis. Soft tissue infiltration over the left middle ear cavity and the external auditory canal were also noted (Fig. 2). With a prognosis of chronic otitis media complicated with mastoiditis, subperiosteal and subcutaneous abscess, he was admitted immediately. We administered intravenous antibiotics (augmentin 1200 mg per 8 hours) and performed modified radical mastoidectomy with type III tympanoplasty on the day of admission. During this operation, a great amount of tenacious discharge was drained from the subcutaneous and subperiosteal spaces. We also identified a bony defect on the mastoid cortex. A large amount of discharge, inflammatory granulations and a huge cholesteatoma occupied the mastoid cavity. Cholesteatoma blocked the aditus ad antrum. Both the malleus and incus were defective; however, the stapes was intact and mobile. After taking some pus for bacterial culture, the tenacious discharge, granulation tissues and cholesteatoma were removed delicately. We inserted a piece of silicon sheet into the middle ear cavity to prevent post-operative adhesion. We took a piece of concha cartilage,

then placed on the stapedius head to complete type III tympanoplasty. This patient was discharged on the seventh day of hospitalization. The result of the pus culture was staphylococcus aureus sensitive to amoxicillin. He recovered uneventfully without recurrence after 5 months' of follow-up.

DISCUSSION

Inadequate treatment of otitis media leads to extensive mucosa swelling and tenacious secretions which may block the aditus ad antrum [1], resulting in inadequate ventilation and drainage of the mastoid cavity and middle ear space. The purulent secretion may accumulate in mastoid air cells and destruct bony septa between the air cells. Broken air cells gradually merge to become a large common cavity, a condition known as coalescent mastoiditis. In advanced cases, abscess may break down the mastoid cortex and penetrate the surrounding tissues [2]. Possible pathways of abscess spreading are described as follows [3,4]: 1) Penetration of the mastoid cortex leads to a subperiosteal abscess, which can further extend to the subcutaneous layer and become a subcutaneous abscess. 2) Extension to the insertion of the sternocleidomastoid muscle forms a Bezold's abscess, which can further extend through cervical fascia and result in deep neck infections. 3) Extension along the zygomatic root forms a zygomatic abscess. 4) Extension inward and forward causes labyrinthitis, petrositis and even facial paralysis. 5) Extension upward and backward causes intracranial complications, such as meningitis, encephalitis, epidural abscess, subdural abscess, brain abscess and hydrocephalus.

Acute mastoiditis and related complications are frequently the result of inadequate treatment of otitis media [1,2,4,5]. Patients with mastoiditis due to underlying cholesteatoma are also reported in undeveloped and developing countries [6]. Some patients may have a family history of chronic suppurative otitis media, while others may have a cleft palate, meningitis, brain

abscess, or may have had previous otological surgery, such as tympanoplasty, mastoidectomy or labyrinthectomy. Attention should be paid to these patients for the possibility of cholesteatoma [5,7]. Although our 2 patients received oral antibiotics, mastoiditis and subperiosteal abscess developed. For most of the patients, oral antibiotics may be adequate for treating otitis media; however, it may be inadequate for some patients. Blockage of the aditus ad antrum may separate the middle ear and mastoid cavity. The middle ear cavity has a better chance to harvest ventilation and drainage from the Eustachian tube, while the mastoid cavity does not. Because of the blockage of the aditus ad antrum, mastoiditis continues to worsen, while otitis media may be resolving. The pathologic factor for the blockage of the aditus ad antrum in case one was edematous mucosa and tenacious secretions. In case two it was cholesteatoma. According to Hawkins [8] and Harley et al [1], when mastoiditis occurs in an older child, we should suspect the presence of cholesteatoma.

According to the literature, the most common pathogens responsible for acute mastoiditis and mastoid abscess are *Streptococcus pneumoniae*, *Streptococcus pyogenes*, *Staphylococcus aureus* and *Hemophilus influenzae* [1,2,9]. Reports of mixed flora have also been presented. Reports of bacteria free mastoiditis are probably due to prior usage of antibiotics.

Infants and young children between 6 months and 3 years are more predisposed to acute mastoiditis [1,9,10]. Furthermore, boys seem to be more prone to it than girls [10,11]. The most common symptoms of acute mastoiditis are pain and fever. The most common local findings are postauricular swelling and erythema [1]. The most common clinical signs of subperiosteal abscess are postauricular swelling, tenderness and fever. Sometimes, abscess formation may push the pinna anteriorly, causing it to protrude. As complications of otitis media are becoming rare, it is difficult for physicians to identify subperiosteal abscesses based on clinical

presentations alone. Symptoms of acute mastoiditis are not always consistent with clinical signs [12]. Nadal et al [9] noted that acute mastoiditis is not always accompanied with acute otitis media. The tympanic membrane of some patients with subperiosteal abscess can appear normal. In our report, for example, the tympanic membrane looked only mildly injected in case one. Case two was brought to our hospital without fever and the white blood cell count was within normal limits. The prior usage of antibiotics had temporarily relieved his symptoms of otorrhea and postauricular pain, and could be the reason that mastoiditis with subperiosteal abscess was not diagnosed in time.

Bony destruction and abscesses on CT scans are helpful in diagnosing mastoiditis. Once intracranial or extracranial complications are highly suspected [12], CT scan can be a useful tool for outlining the relationship between the extent of the abscess and the related landmarks. Intracranial, subperiosteal and cervical abscesses are indications that surgical intervention is necessary.

Mild cases of acute mastoiditis need conservative treatment. A ventilation tube should be inserted if there is evidence of accumulated mucopus in the middle ear cavity [5,8]. Once intracranial complications, coalescent mastoiditis, mastoid abscess, subperiosteal abscess or cholesteatoma have occurred, or the disease is resistant to conservative treatments, surgery is advised in order to prevent further deterioration [1,4]. Intravenous antibiotic treatment should be used after surgery and continued until the subsidence of symptoms, such as pain, fever and swelling. As the condition becomes stable, the patients can be discharged and prescribed oral antibiotics. Regular follow-up is also suggested.

The management of mastoiditis and subperiosteal abscesses relies on antibiotics and adequate surgical intervention; however, it is controversial whether to adapt one-stage or two-stage surgery for patients who have

cholesteatoma, mastoiditis and subperiosteal abscess at the same time [5,7]. On the one hand, Primrose and Cinnamon [7] advocate two-stage surgery. They perform simple mastoidectomy first to drain the abscess and then perform modified radical mastoidectomy in second stage to remove the cholesteatoma and related diseases. This policy may be good for minimizing possible surgical complications such as facial paralysis, and sensorineural hearing loss. On the other hand, concerning the low incidence rate of surgical complications, Magliulo et al [5] preferred one-stage surgery.

Subperiosteal abscesses are becoming rare in developed countries, including Taiwan. Because the complications of mastoiditis and subperiosteal abscesses can be fatal, attention should be paid to the clinical features. If we keep in mind the early symptoms and signs of the complications of otitis media, an early diagnosis can be made.

REFERENCES

1. Harley EH, Sdralis T, Berkowitz RG. Acute mastoiditis in children: a 12-year retrospective study. *Otolaryngol Head Neck Surg* 1997;116:26-30.
2. Moisa II, Danziger EJ, Brauer RJ. Subperiosteal and Bezold's abscesses complicating cholesteatoma: a case report. *Otolaryngol Head Neck Surg* 1987; 97:399-402.
3. Jeng FC, Hung CM. Acute mastoiditis complicated with subperiosteal abscess-case report. *J Taiwan Otolaryngol Head Neck Surg* 1997;32:328-32.
4. Goldstein NA, Casselbrant ML, Bluestone CD, et al. Intratemporal complications of acute otitis media in infants and children. *Otolaryngol Head Neck Surg* 1998;119:444-54.
5. Magliulo G, Vingolo GM, Petti R, et al. Acute mastoiditis in pediatric age. *Int J Pediatr Otorhinolaryngol* 1995;31:147-51.
6. Ibekwe AO, Okoye BC. Subperiosteal mastoid abscess in chronic suppurative otitis media. *Ann Otol Rhinol Laryngol* 1988;97:373-5.
7. Primrose WJ, Cinnamon MJ. Acute mastoid abscess and cholesteatoma. *Int J Pediatr Otorhinolaryngol* 1987;12:229-35.
8. Hawkins DB, Dru D, House JW, et al. Acute Mastoiditis in children: a review of 54 cases. *Laryngoscope* 1983;93:568-72.
9. Nadal D, Herrmann P, Baumann A, et al. Acute mastoiditis: clinical, microbiological, and therapeutic

- aspects. *Eur J Pediatr* 1990;149:560-4.
10. Spratley J, Silveira H, Alvarez I, et al. Acute mastoiditis in children: review of the current status. [Review] *Int J Pediatr Otorhinolaryngol* 2000;56:33-40.
 11. Josen R. Acute suppurative otitis media and acute mastoiditis. *Scott-Brown's Otolaryngology*. London: Butterworths, 1987:177-93.
 12. Spiegel JH, Lustig LR, Lee KC, et al. Contemporary presentation and management of a spectrum of mastoid abscesses. *Laryngoscope* 1998;108:822-8.

兒童急性乳突炎併發骨膜下膿瘍：二例報告

張煜謙 鄭富城 林嘉德 蔡銘修

中國醫藥學院附設醫院 耳鼻喉部

自從開始使用抗生素以來，中耳炎引發急性乳突炎及乳突骨膜下膿瘍等併發症的發生率已經顯著減少。本部最近經歷2名病例，第1位是4歲男童因右側急性中耳炎引發急性乳突炎，合併有骨膜下膿瘍，而接受右側單純乳突切開術及鼓膜切開術並放置通氣管，術中發現膿液堆積於中耳腔及乳突竇，並且侵蝕到骨膜下層，鼓竇入口被腫脹黏膜及膿液所阻塞。第2位是1名13歲男童因左側慢性中耳炎及膽脂瘤引發急性乳突炎，亦合併有骨膜下膿瘍，而接受改良式根治性乳突切開術及第三型鼓室成型術，清除位於皮下組織、骨膜下層及乳突竇之膿液，隨後發現一巨大膽脂瘤充滿乳突竇及中耳腔，並且阻塞鼓竇入口。2名患者於住院期間均輔以靜脈抗生素治療，術後恢復情況良好，於門診追蹤迄今各13個月及5個月，並無復發跡象。（中台灣醫誌 2001;6:179-84）

關鍵詞

急性乳突炎，骨膜下膿瘍

聯絡作者：張煜謙

地址：404台中市北區育德路2號

中國醫藥學院附設醫院 耳鼻喉部

收文日期：6/21/2001

修改日期：8/10/2001

接受日期：8/13/2001