

- fingers:
I. pollex
II. digitus indicis
III. digitus medius
IV. digitus annularis
V. digitus minimus

brachioradialis
muscle

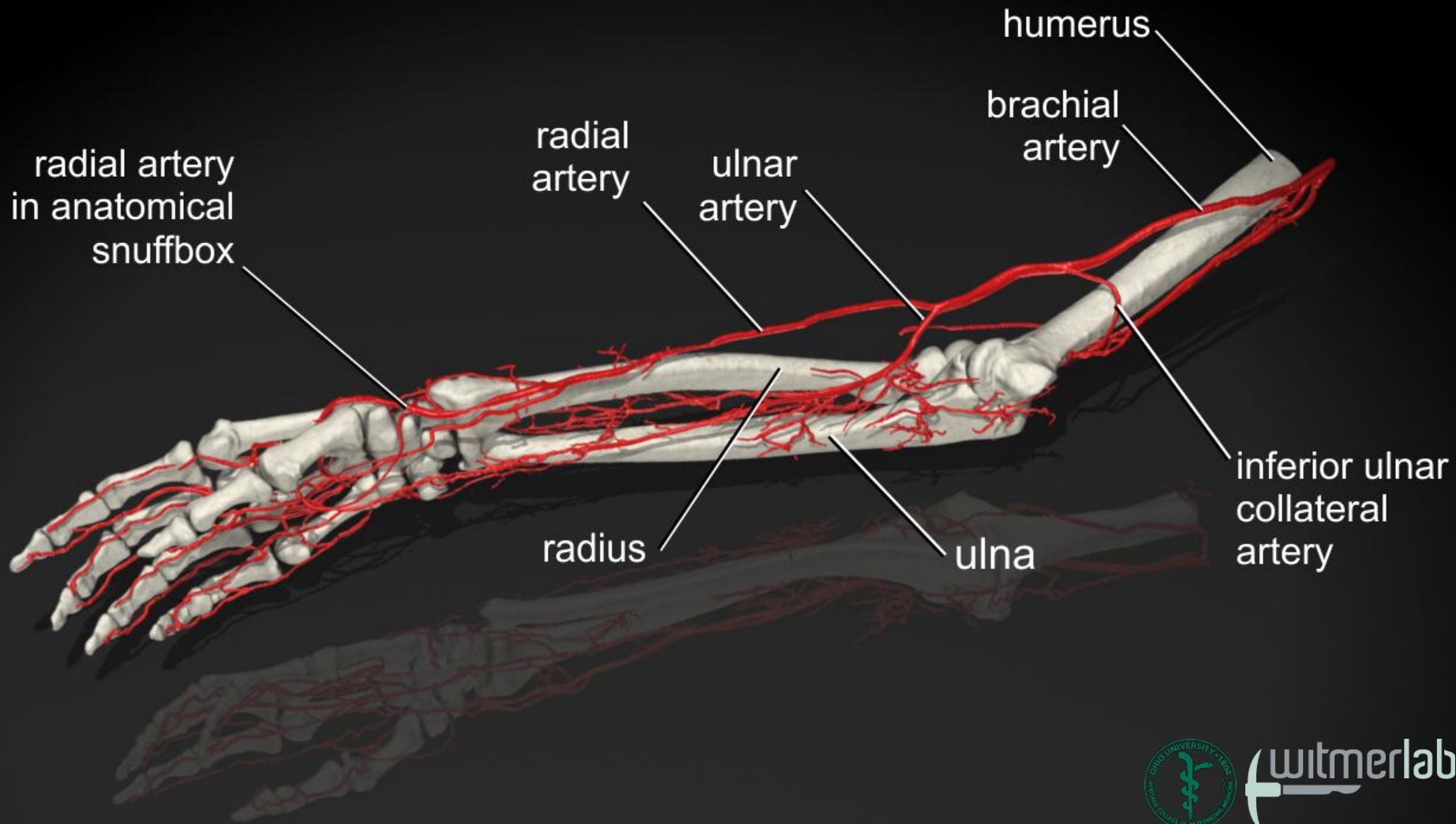
cubital
fossa

medial
epicondyle
of humerus

thenar
eminence

hypothenar
eminence

- I
II
III
IV
V



humerus

brachial
artery

radial
artery

ulnar
artery

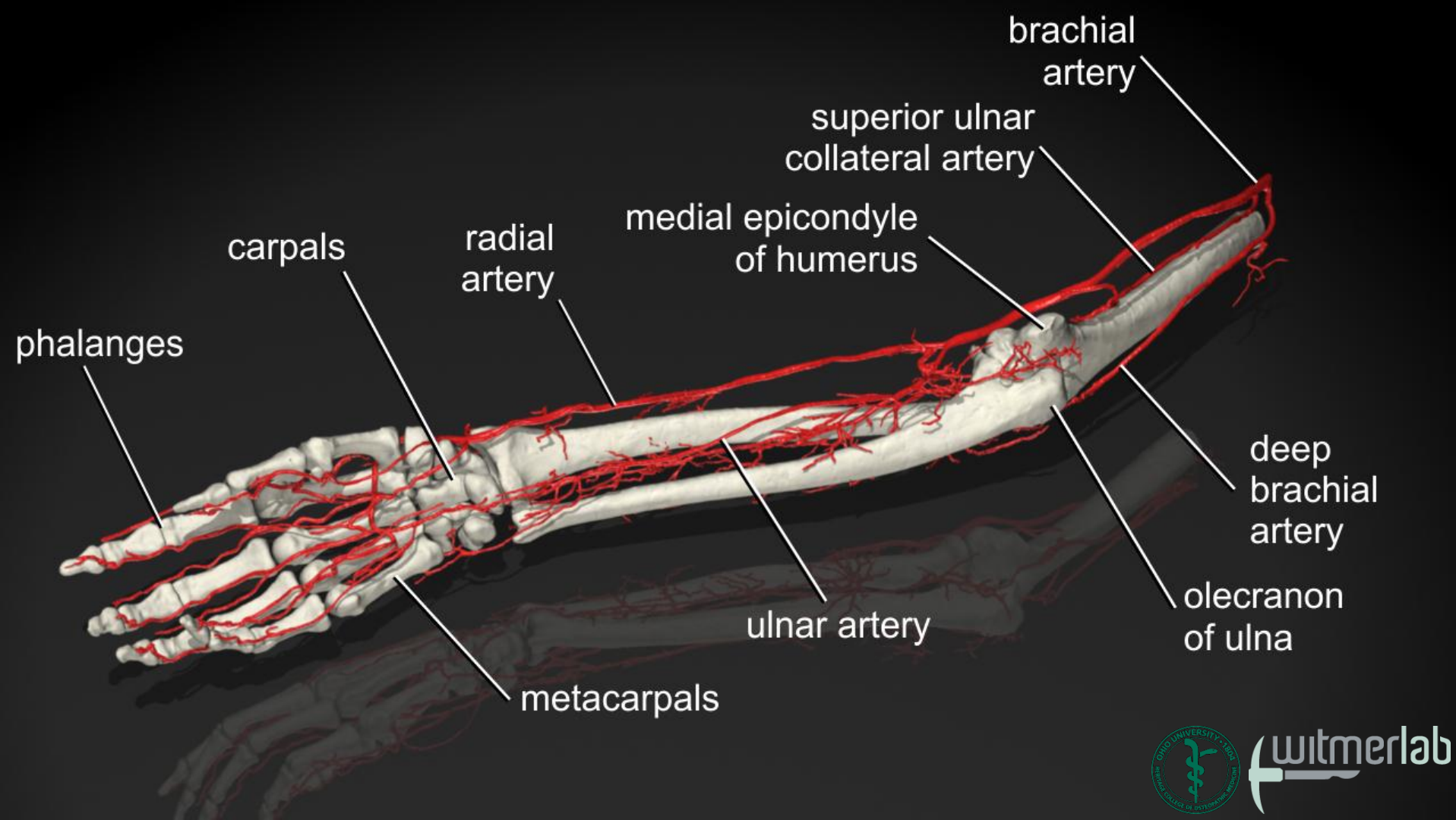
radial artery
in anatomical
snuffbox

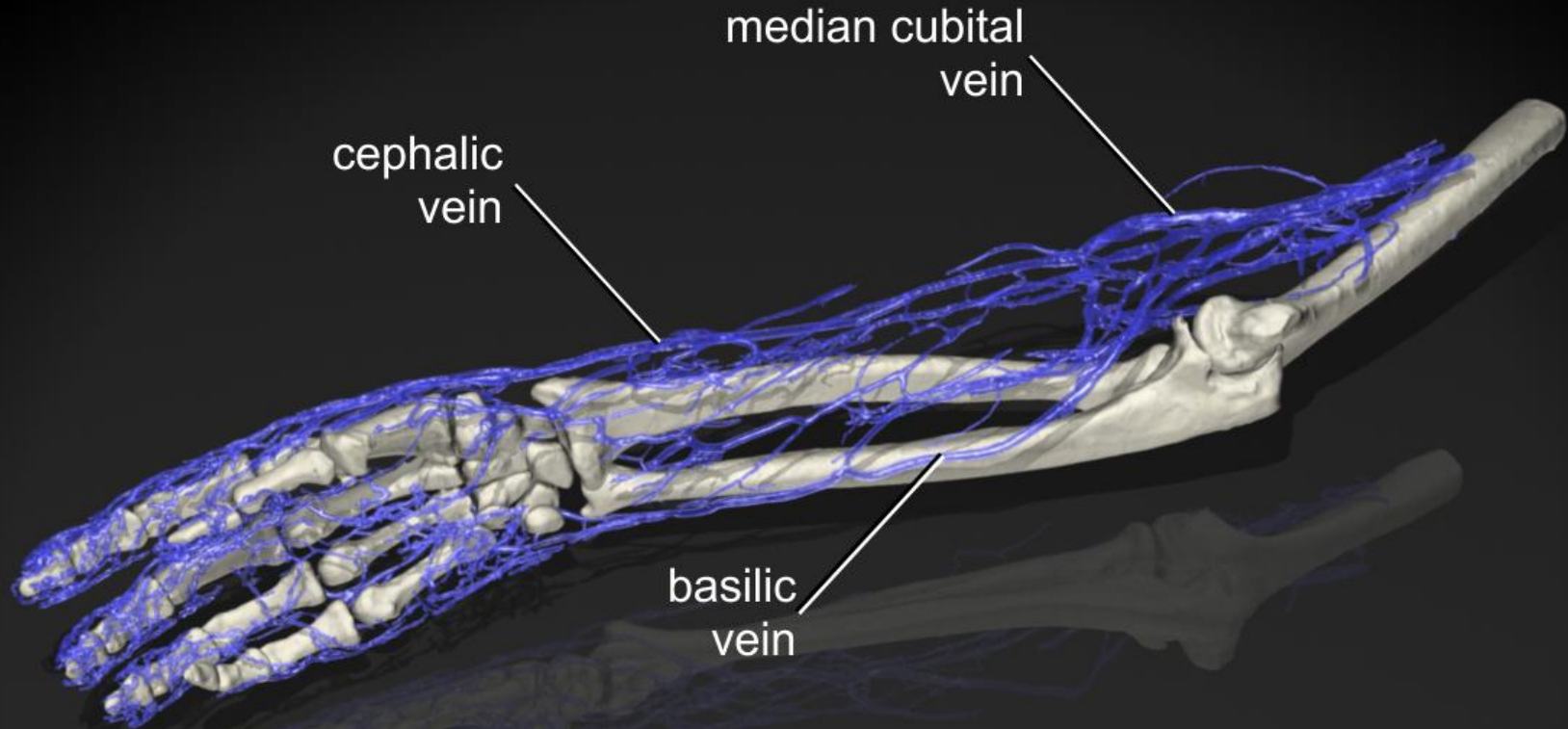
inferior ulnar
collateral
artery

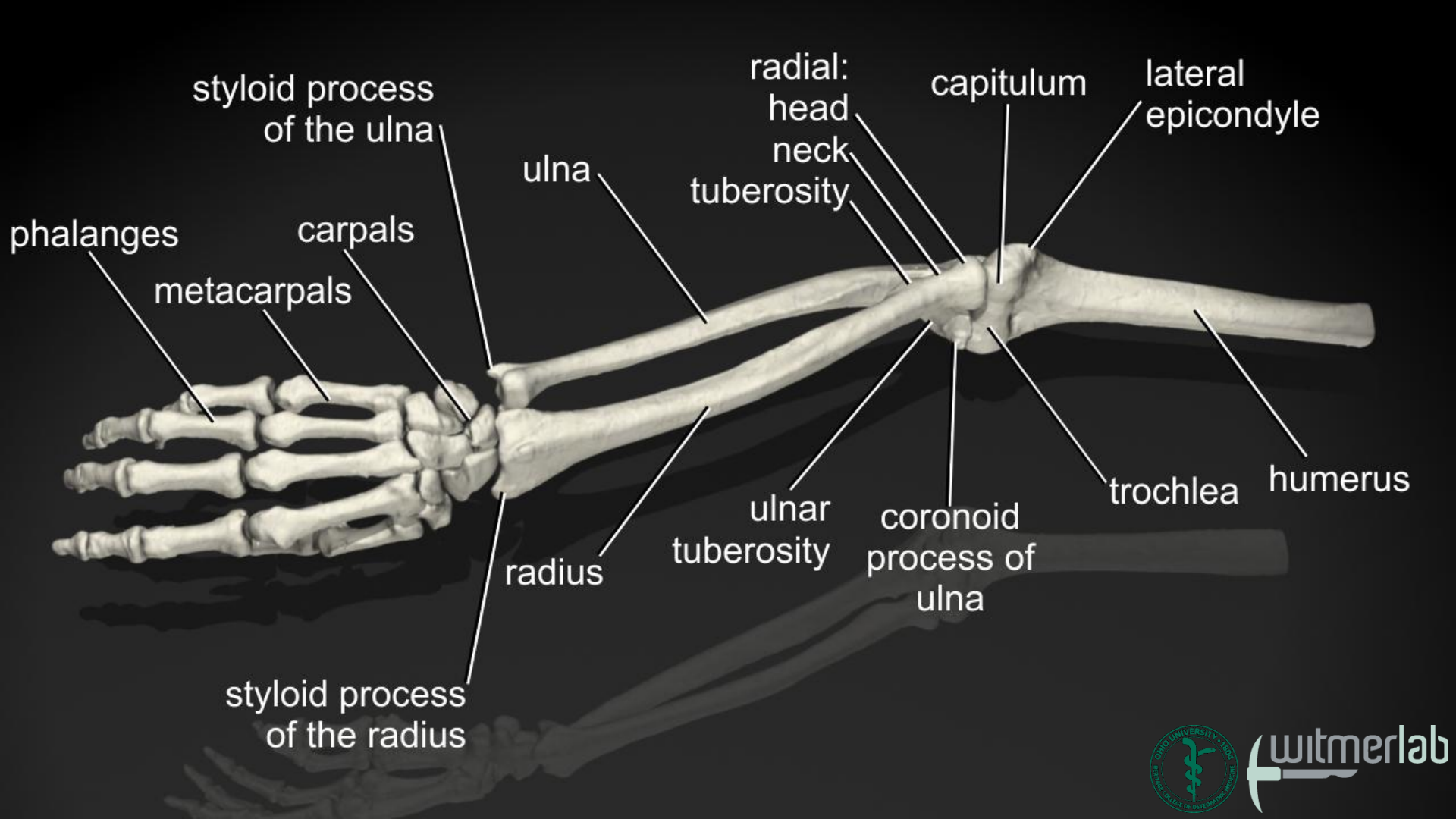
radius

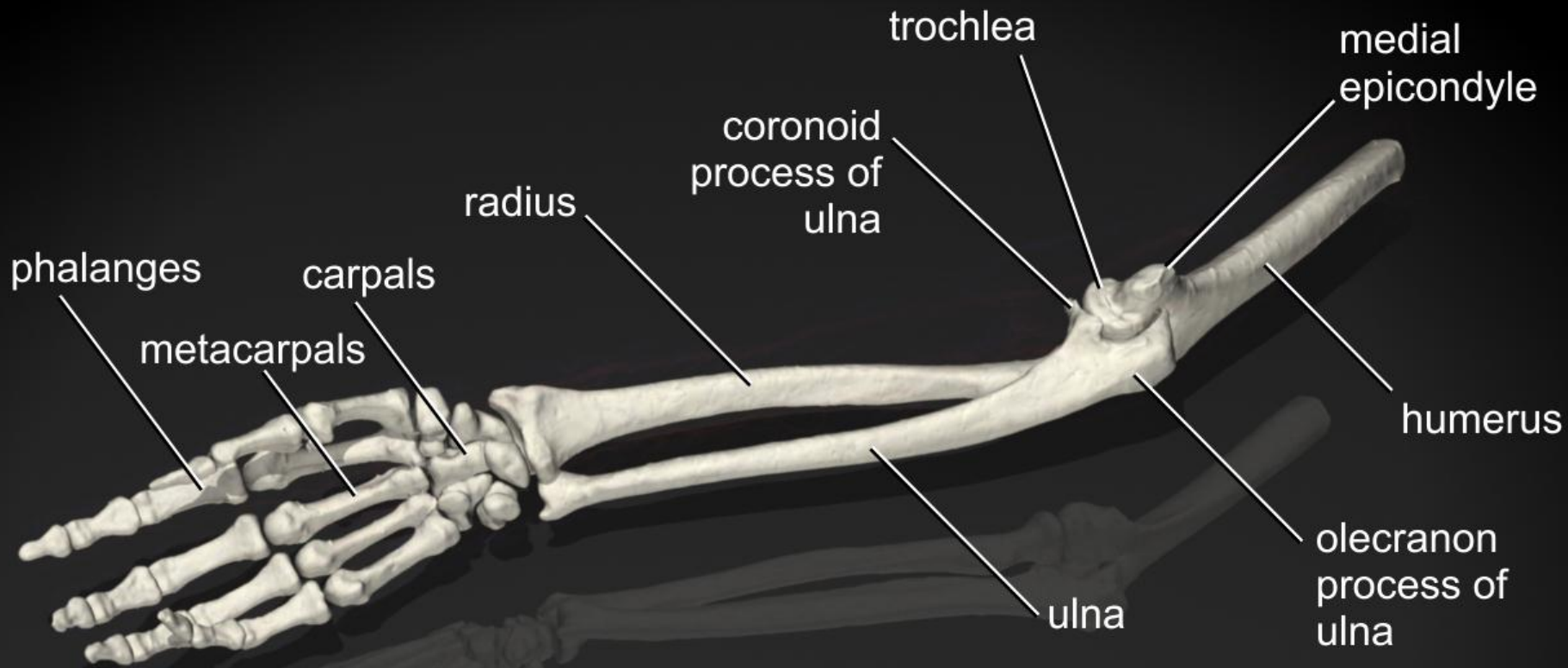
ulna

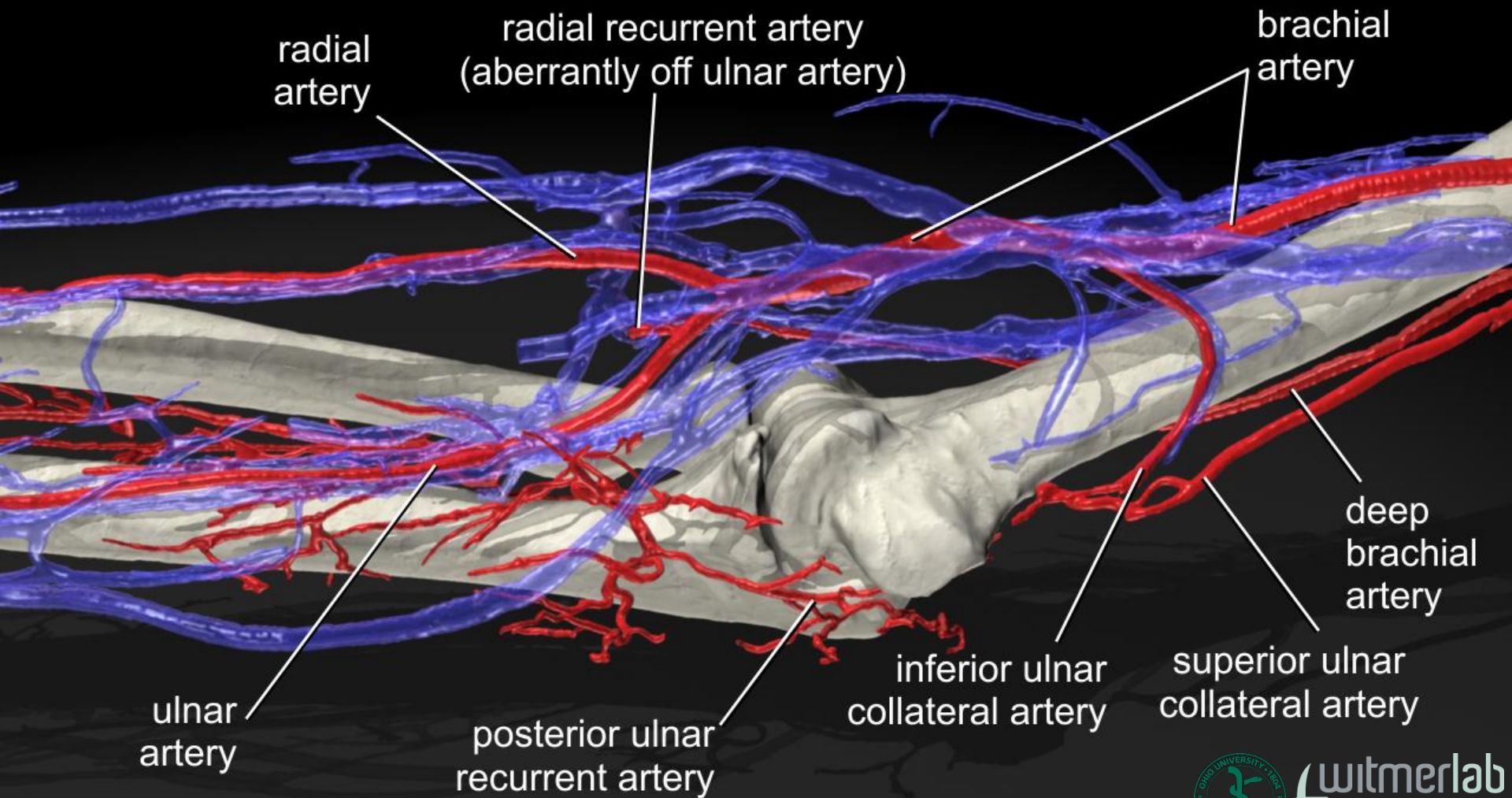


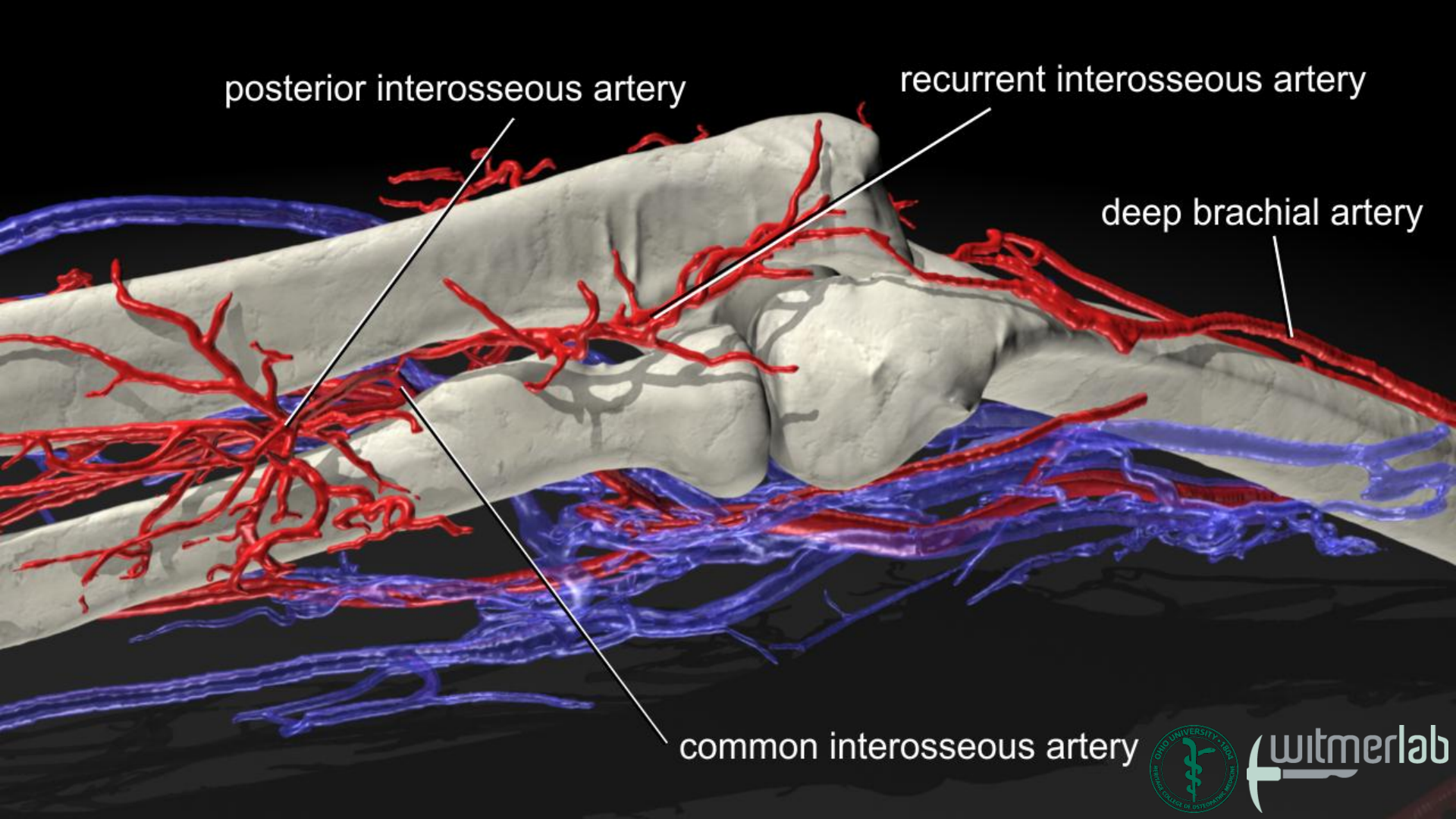












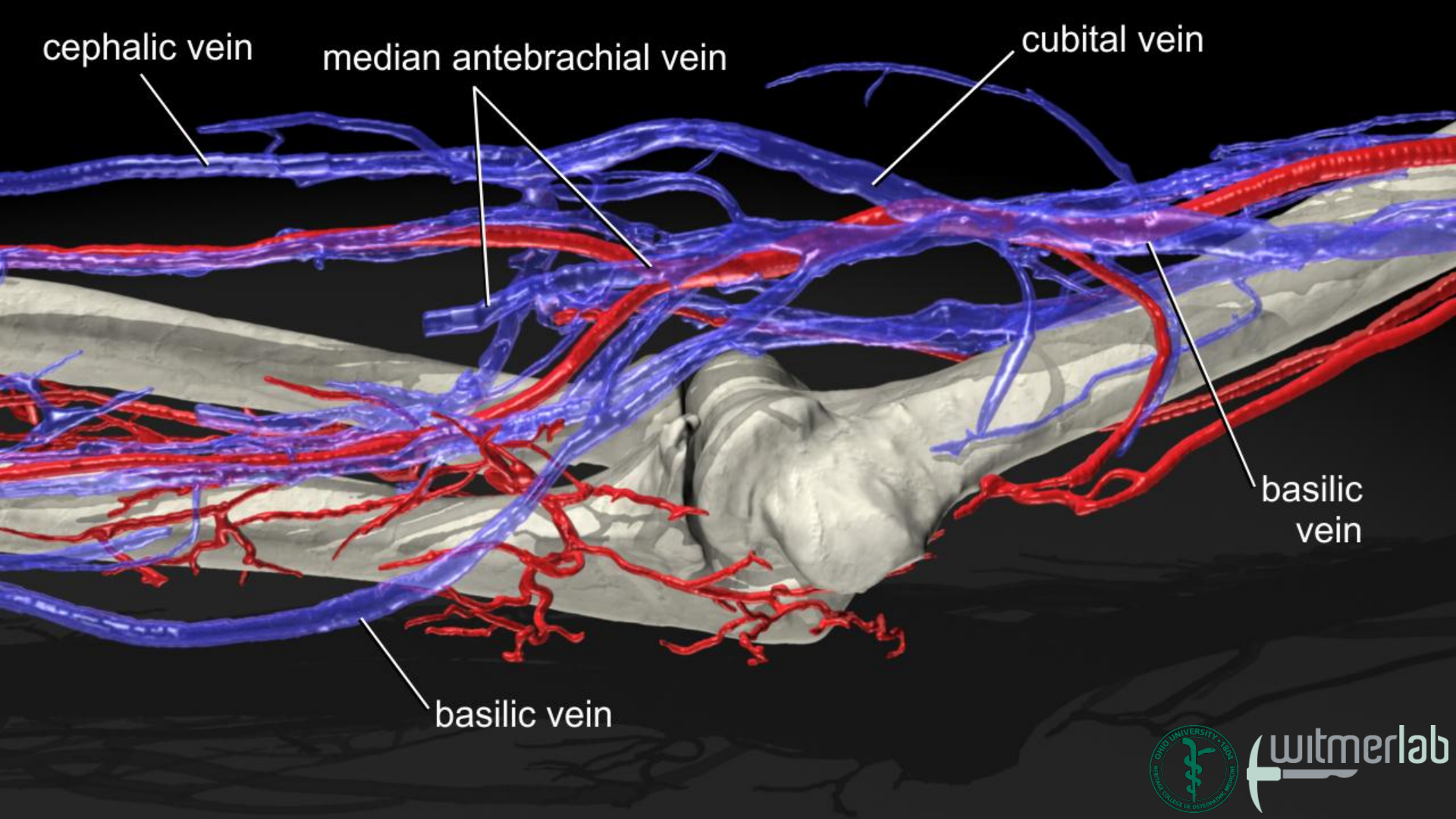
posterior interosseous artery

recurrent interosseous artery

deep brachial artery

common interosseous artery





cephalic vein

median antebrachial vein

cubital vein

basilic vein

basilic vein

