

Reprint Series

3 August 2001

# Science

Vol. 293 No. 5531  
Pages 749-1000 \$9



AMERICAN ASSOCIATION FOR THE ADVANCEMENT OF SCIENCE

# Nostril Position in Dinosaurs and Other Vertebrates and Its Significance for Nasal Function

Lawrence M. Witmer

Many dinosaurs have enormous and complicated bony nasal apertures. Functional interpretation requires knowledge of the location of the external opening in the skin. Traditionally, the fleshy nostril of dinosaurs has been placed in the back of the bony opening, but studies of extant dinosaur relatives suggest that it is located far forward. Narial blood supply and cavernous tissue corroborate the rostral position in dinosaurs. A rostral nostril was, and remains, a virtually invariant rule of construction among Amniota, which has consequences for (i) nasal airstreaming, and hence various physiological parameters, and (ii) the collection of behaviorally relevant circumoral odorants.

Nasal structures play a role in many well-studied biological functions, ranging beyond olfaction and respiration to manipulation, behavioral display, and thermal physiology (1). A neglected aspect is the external opening in the skin, the fleshy nostril. In many vertebrates, the osseous nasal aperture (i.e., bony nostril) is much larger than the fleshy nostril. For example, the bony nostril and nasal vestibule (the rostralmost portion of the nasal cavity) were enormous in such dinosaur clades as sauropods (the long-necked brontosaurus; Fig. 1A), hadrosaurines (the duck-billed dinosaurs), and ceratopsids (*Triceratops* and its kin), occupying as much as half the length of the skull. Where within the huge bony nostril was the much smaller fleshy nostril located? The most commonly portrayed site has been in the caudal or caudodorsal portion of the bony nostril (Fig. 1A, *d* and *e*), but no one has tested this hypothesis. What factors govern the position and form of the fleshy nostril in amniotes generally, and what impact do these have on nasal function, and hence, physiology and behavior?

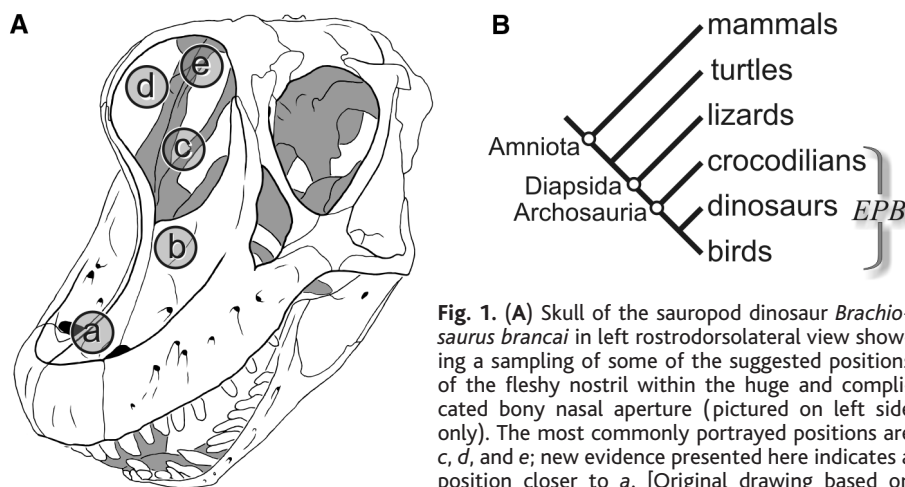
Here, I investigate the fleshy nostril in amniotes using the extant phylogenetic bracket (EPB) approach (2, 3) for the reconstruction of attributes not normally preserved in fossil material. Extant organisms provide the only opportunity to directly observe the relationships between the fleshy and bony nostrils. The first two extant outgroups of a fossil taxon are most relevant, because they phylogenetically “bracket” the extinct taxon and hence constrain all inferences (2). Thus, for any particular clade of dinosaurs, extant birds and

crocodilians are most pertinent, although I also sampled representatives of successively more distant extant amniote clades (Fig. 1B). To simultaneously visualize both fleshy and bony nostrils, I used a modification of plain-film radiography involving stereoscopic imaging coupled with radiolabeling of the fleshy nostril (Fig. 2) (4). I used this technique on 62 animals, encompassing 45 species of extant Diapsida in 26 traditional families of birds, one family of crocodilians, and four families of lizards [see supplementary material (5)]. The null hypothesis being tested was that there is no consistent relation, and that the fleshy nostril is not constrained to be in any one location within the bony nostril.

The results of these radiographic studies allowed rejection of the null hypothesis in that there was an almost completely invariant pattern among the diapsid taxa sampled: in virtually all cases, the fleshy nostril is

located far rostrally within the bony nostril (Fig. 2). The front of the fleshy nostril in some taxa extended rostrally beyond the front of the bony nostril (e.g., *Uromastyx*, *Anser*, *Megaceryle*), but, in most cases, it was just caudal (e.g., *Alligator*, *Struthio*, *Spheniscus*, *Fulica*) or coincident with the front of the bony nostril (e.g., *Dromaius*, *Bubo*, *Larus*). In most cases, the fleshy nostril was not just rostral but rostroventrally positioned (Fig. 2). The fleshy nostril was never located in a caudalmost position. In rare cases, the general rostroventral pattern was not observed, but these are easily interpretable apomorphic exceptions (6). The fleshy nostril was not always flush with the margin of the bony naris, but rather was often extended peripherally by narial soft tissues (e.g., cartilage, dense connective tissues). This was the case for the lizards and crocodilians sampled, as well as some of the birds (e.g., *Anser*), but in other birds (e.g., *Struthio*) the fleshy nostril was nearly level with the bony nostril.

Other amniote outgroups showed similar relationships. In most turtles and mammals, the bony nostril is terminal, and hence, the fleshy nostril by necessity will be rostral to the bony nostril, just as in the vast majority of diapsids. Moreover, in mammals (and humans are a typical example) and turtles, the fleshy nostril is pushed rostrally or rostroventrally well beyond the bony nostril by nasal cartilages. Thus, more basal amniotes provide further support for rejection of the null hypothesis. There is indeed a strong and consistent signal indicating that the primitive amniote condition, retained in all but a clade or two, is for the fleshy nostril to be rostrally or rostroventrally positioned within the bony nostril.



**Fig. 1. (A)** Skull of the sauropod dinosaur *Brachiosaurus brancai* in left rostradorsolateral view showing a sampling of some of the suggested positions of the fleshy nostril within the huge and complicated bony nasal aperture (pictured on left side only). The most commonly portrayed positions are *c*, *d*, and *e*; new evidence presented here indicates a position closer to *a*. [Original drawing based on specimens in the Museum für Naturkunde der Humboldt-Universität, Berlin] **(B)** Phylogenetic relationships and clade names of the major taxa discussed in the text. For assessing unpreserved attributes of extinct nonavian dinosaurian taxa, the most informative extant taxa are crocodilians and birds, which together form the extant phylogenetic bracket (EPB) of a particular dinosaur (2).

Department of Biomedical Sciences, College of Osteopathic Medicine, Ohio University, Athens, OH 45701, USA.

E-mail: witmer@exchange.oucom.ohiou.edu

relationships and clade names of the major taxa discussed in the text. For assessing unpreserved attributes of extinct nonavian dinosaurian taxa, the most informative extant taxa are crocodilians and birds, which together form the extant phylogenetic bracket (EPB) of a particular dinosaur (2).



## REPORTS

Patterns of narial blood supply also are informative with regard to fleshy nostril position. Analyses of diapsid cephalic blood supply in general (7, 8) and dinosaurian facial blood supply in particular (9) show that a rich nasal vestibular vascular plexus (NVVP) can be homologized across at least diapsids, if not all amniotes (7). The NVVP is located in the narial region within the area generally bounded by the bony nostril and near the fleshy nostril. In many clades, the NVVP takes the form of a cavernous (erectile) tissue mass that compresses the nasal vestibule and fleshy nostril to varying extents. Narial cavernous tissue associated with the fleshy nostril has been well documented in crocodylians (10, 11), lizards (8, 12, 13), and turtles (14, 15);

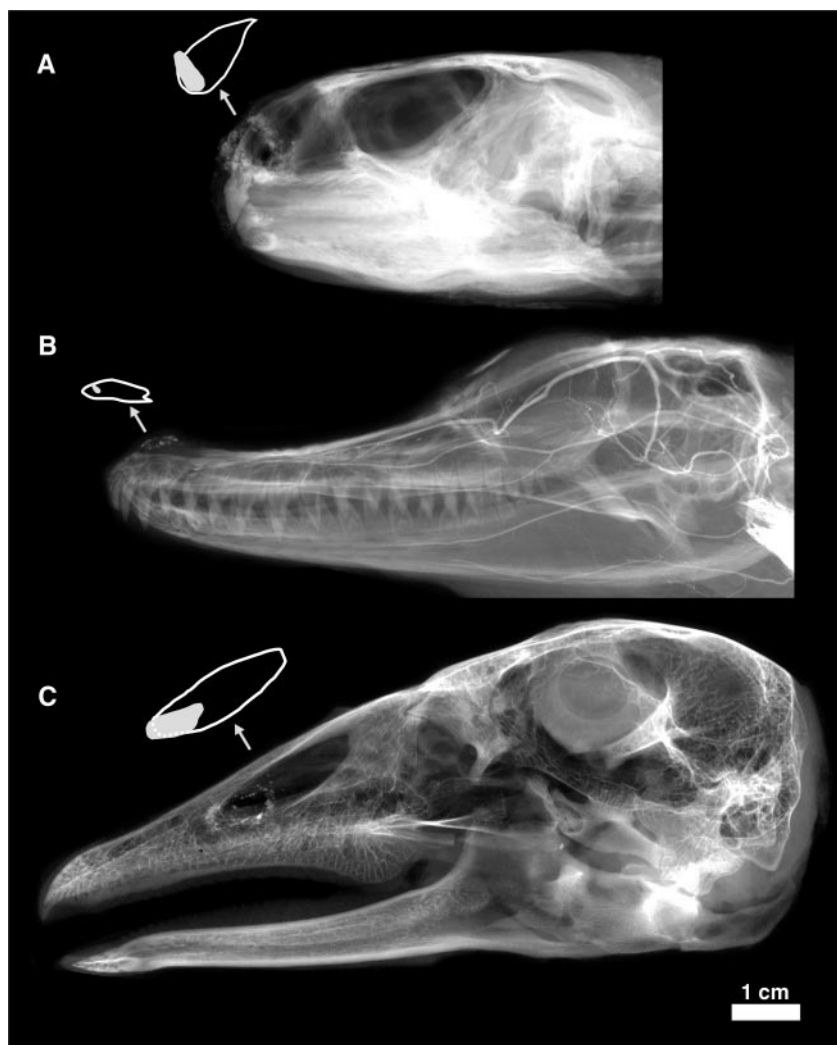
birds (16) and mammals (17) have cavernous tissue associated with their nasal conchae. Blood supply to narial cavernous tissue is remarkably consistent and results in osteological correlates (e.g., foramina, grooves) that in turn provide general information on the position of the fleshy nostril (7). These osteological correlates of narial blood supply were surveyed in dinosaur taxa (9) and are consistent with similar masses of narial cavernous tissue. The inferred narial cavernous masses in dinosaurs are all located rostrally or rostroventrally within the bony nostril, which is in accord with the results of the radiographic study.

These findings suggest that, in dinosaurs, the fleshy nostril was located far rostrally within the narial region (Fig. 1A,

Fig. 3C), not in the back as it is usually portrayed (Fig. 1A, e; Fig. 3B). According to phylogenetic character optimization theory and its application within the EPB approach, the inference is a decisive, positive assessment [i.e., a level I (or I') inference] (2). That is, it would be more speculative and less parsimonious to place it in its traditional caudal position (18), because it would be virtually unique among known amniotes.

The position of the fleshy nostril is relevant, not just in dinosaurs but in all amniotes, to a variety of physiological and behavioral functions relating to the upper respiratory and olfactory systems. For example, the site of air intake is critical for models of nasal dynamics and airstreaming, as shown for both birds (19) and mammals (20), in that it largely dictates the course of airflow over the nasal epithelium. Sauropods, hadrosaurines, and ceratopsids not only have enlarged bony nostrils but also have relatively complicated nasal vestibules, with a variety of crests and recesses that served to increase nasal epithelial surface area as well as foramina and canals that transmitted a rich vascular supply (Figs. 1A and 4). All evidence indicates that these dinosaurs had some kind of apparatus or physiological device lodged in this complex narial region that involved interaction of the upper respiratory system with the blood vascular system, with implications for dinosaur thermal biology (9). Thus, if the fleshy nostril were located in its traditional caudal position (Fig. 4B), then most of the narial apparatus would be out of the main airstream and instead in a cul-de-sac, which, from a design standpoint, seems problematic. On the other hand, if the fleshy nostril were located rostrally or rostroventrally (Fig. 4C), then the narial apparatus would be fully within the air flow, allowing the apparatus to participate more effectively in, for example, forced convective heat loss, facilitated evaporative cooling, and intermittent countercurrent heat exchange—processes that play a role in heat and water balance and in selective brain temperature regulation (21–26).

Thus, given the importance of the nose and nasal cavity in animal physiology, it perhaps should not be surprising that the up-front position of the fleshy nostril is so consistent within amniotes. But there may be more to nostril position than just its role in conveying an airstream across the nasal apparatus. Olfaction remains important in many extant amniote groups, being intimately associated with critical behaviors (e.g., feeding, reproduction, predator detection, territoriality), and it has been argued that some dinosaurs had significant olfac-



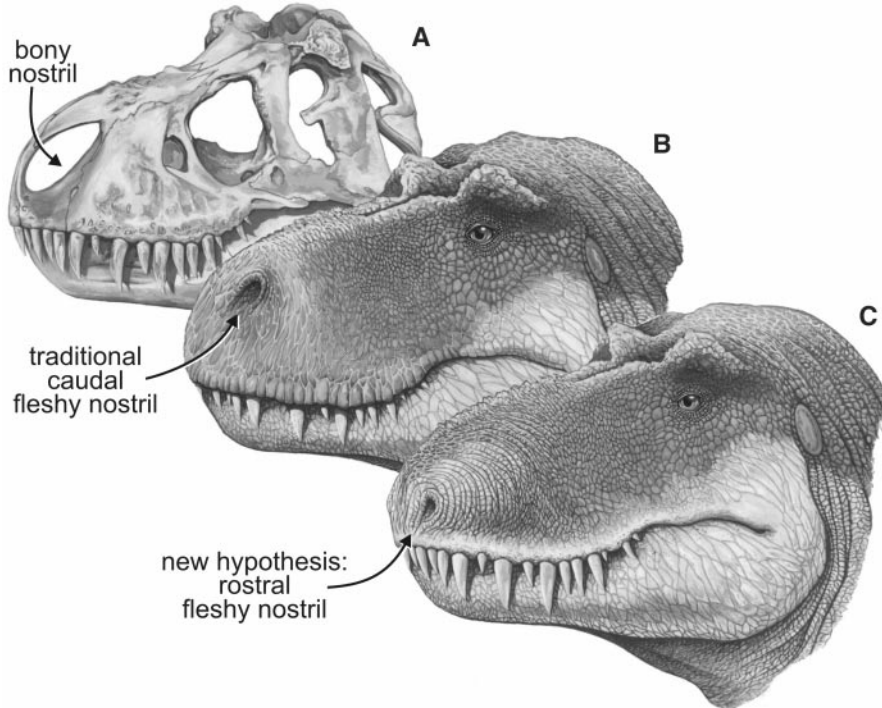
**Fig. 2.** Lateral plain-film radiographs of diapsid heads showing the relationship of the fleshy nostril to the bony nostril. In all cases, the fleshy nostril has been made radiodense by labeling with barium sulfate (granular densities). Each image is one of a set of stereoscopic radiographs. Adjacent to the narial region of each animal is a tracing of both the bony nostril (white line) and the fleshy nostril (filled gray shape). The observed relationships are nearly ubiquitous for amniotes: the fleshy nostril is located far rostrally within the bony nostril, in most cases being ventrally situated, as well. (A) *Uromastyx aegypticus*, spiny-tailed lizard (Squamata: Agamidae). (B) *Alligator mississippiensis*, American alligator (Crocodylia, Alligatoridae). (C) *Anser anser*, domestic goose (Anseriformes, Anatidae).

## REPORTS

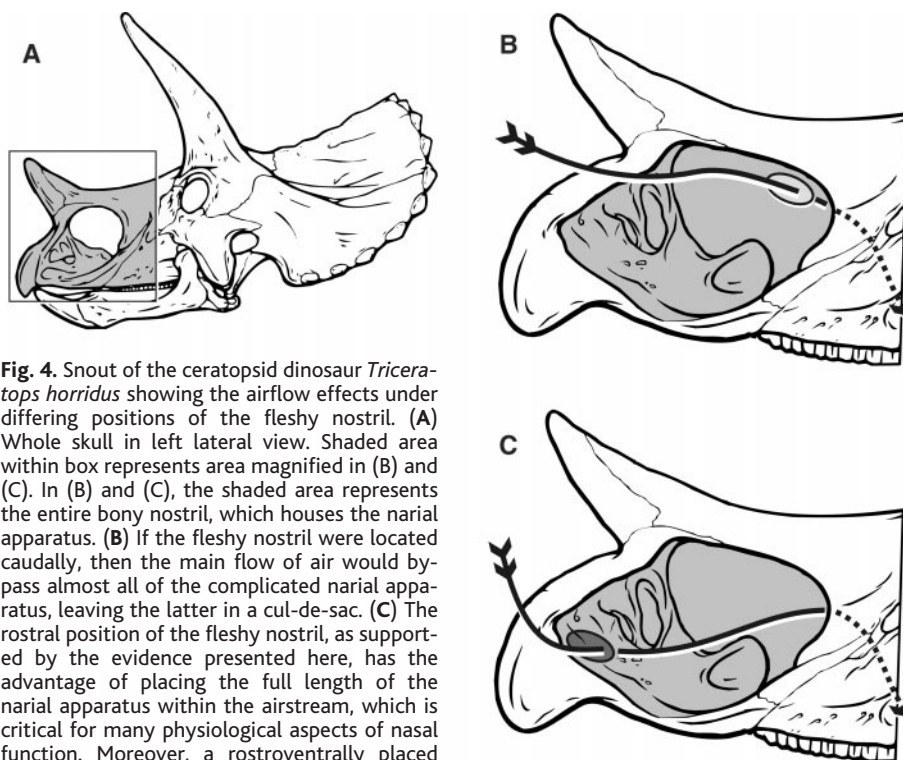
tory capabilities (27, 28). Locating the fleshy nostril rostrally and ventrally thus facilitates collecting odorants from the area

immediately in front of the animal and adjacent to the oral cavity. Varanid lizards, some members of which are the rare excep-

tion to the rostral nostril rule (6), provide a test of this hypothesis. The enlarged vomeronasal organ (VNO) of some varanids diverts the fleshy nostril caudally, potentially decreasing the effectiveness of conveying conventional olfactory stimuli from the circumoral area. Varanids have a relatively poor sense of smell (29). Diminished conventional olfaction may be tolerated because varanids have emphasized the alternate chemosensory mode of the VNO. Although birds almost universally manifest the fundamental rostral position of the fleshy nostril within the bony nostril, their entire narial apparatus is often located caudally or even caudodorsally on the bill. With some exceptions (19), birds have relatively poor olfactory capabilities, suggesting that, like varanids, regression of the narial apparatus from the circumoral region has not been selectively disadvantageous. More importantly, however, birds have co-opted the prenasal portion of the skull for feeding and behavioral roles, expanding the premaxillary bones rostrally and, in a sense, leaving the narial apparatus behind.



**Fig. 3.** Skull and fleshed-out restorations of the head of the nonavian theropod dinosaur, *Tyrannosaurus rex*, in left rostradorsolateral view showing the bony nostril and varying views of the position of the fleshy nostril. (A) Skull, showing the bony nostril; note also the narial fossa on the bones adjacent to the opening. (B) Head showing the caudal position of the fleshy nostril typically depicted in most scientific and popular restorations. (C) Head showing the rostral position of the fleshy nostril supported by the data presented here.



**Fig. 4.** Snout of the ceratopsid dinosaur *Triceratops horridus* showing the airflow effects under differing positions of the fleshy nostril. (A) Whole skull in left lateral view. Shaded area within box represents area magnified in (B) and (C). In (B) and (C), the shaded area represents the entire bony nostril, which houses the narial apparatus. (B) If the fleshy nostril were located caudally, then the main flow of air would bypass almost all of the complicated narial apparatus, leaving the latter in a cul-de-sac. (C) The rostral position of the fleshy nostril, as supported by the evidence presented here, has the advantage of placing the full length of the narial apparatus within the airstream, which is critical for many physiological aspects of nasal function. Moreover, a rostroventrally placed nostril is well disposed to collect circumoral olfactory stimuli. Base drawings modified from (39) and various museum specimens.

### References and Notes

1. L. M. Witmer, *Nat. Hist.* **110**, 64 (2001).
2. ———, in *Functional Morphology in Vertebrate Paleontology*, J. J. Thomason, Ed. (Cambridge Univ. Press, New York, 1995), pp. 19–33.
3. ———, *Mem. Soc. Vertebr. Paleontol. J. Vertebr. Paleontol.* **17**, 173 (1997).
4. To enhance its radiodensity, the margin of the fleshy nostril was radiolabeled by carefully painting it with latex and then sprinkling barium sulfate on the latex. To solve the superimposition problem encountered with any radiograph (e.g., in a lateral radiograph, superimposition of left- and right-sided structures into a single plane), stereoscopic radiographs were made by x-raying each specimen twice at slightly different angles and then viewing the radiographs together with a stereoviewer, restoring three-dimensionality. For most specimens, dorsal and lateral stereoradiographic sets were obtained. When scoring the extent of the bony nostril, any narial fossae on the adjacent premaxilla and maxilla were included because they are functionally part of the narial apparatus.
5. Supplemental material is available at Science Online at [www.sciencemag.org/cgi/content/full/293/5531/850/DC1](http://www.sciencemag.org/cgi/content/full/293/5531/850/DC1)
6. The rare exceptions to the pattern of a rostrally positioned fleshy nostril are easily understood. For example, the sampled cormorant (*Phalacrocorax*) simply lacked a fleshy nostril altogether (a diving adaptation), and the bony nostril of geckos is so small that the fleshy nostril occupied almost its entire extent. The most significant exception was among monitor lizards (*Varanus*). Whereas some species (e.g., *V. komodoensis*, *V. giganteus*) resemble other diapsids in having a rostrally positioned fleshy nostril, other species (e.g., *V. griseus*, *V. dumerilii*, *V. exanthematicus*) have a fleshy nostril located in the middle to caudal half of the much enlarged bony nostril. The modifications of the nasal apparatus resulting in retraction of the fleshy nostril are almost certainly associated with apomorphic elaboration of the chemosensory VNO, which is enlarged relative to other lizards (29) and, almost unique among squamates, lies rostral to the fleshy nostril (30, 31); thus, the enlarged VNO apparatus essentially diverts the nostril caudally in some varanids. Given the diversity of amniotes, one would expect to find additional exceptions,



particularly in lizards and birds, which commonly have derived nasal vestibules. The dearth of exceptions in the face of this diversity emphasizes the fundamental nature of the relationship.

7. J. C. Sedlmayr, L. M. Witmer, *J. Vertebr. Paleontol.* **19**, 74A (1999).
8. S. J. Rehorek, A. H. Savitsky, L. M. Witmer, paper presented at the 2001 Annual Meeting of the American Society of Ichthyology and Herpetology, State College, PA, July 2001.
9. L. M. Witmer, S. D. Sampson, *J. Vertebr. Paleontol.* **19**, 85A (1999).
10. A. d'A. Bellairs, C. C. D. Shute, *J. Anat.* **87**, 367 (1953).
11. L. M. Witmer, *J. Morphol.* **225**, 269 (1995).
12. H. L. Bruner, *Am. J. Anat.* **7**, 1 (1908).
13. R. C. Stebbins, *Am. J. Anat.* **83**, 183 (1948).
14. W. F. Walker, *Copeia* **1959**, 257 (1959).
15. T. S. Parsons, in *Biology of the Reptilia*, C. Gans, T. S. Parsons, Eds. (Academic Press, New York, 1970), vol. 2, pp. 99–191.
16. J. J. Baumel, A. F. Dalley, T. H. Quinn, *Zoomorphology* **102**, 215 (1983).
17. J. D. K. Dawes, M. M. L. Prichard, *J. Anat.* **87**, 311 (1953).
18. Why did anyone ever place the nostril caudally in dinosaurs? All leading early paleontologists regarded the largest dinosaurs (sauropods) as primarily "amphibious" (32–35). This view was clinched by the discovery in the sauropod *Diplodocus* of a large caudodorsal nasal opening (36) that was thought to serve as a snorkel, allowing the nearly submerged dinosaur to breathe (the dorsal opening in *Diplodocus* is actually just the caudal portion of the bony nostril, and the rostral portion extends far forward as a shallow narial fossa; vascular relationships confirm a rostral nostril). Although sauropods were later interpreted as terrestrial (37), the inferred caudal nostril stuck and somehow was transferred to other dinosaurs. Retracted nasal bones perhaps could be evidence, but nasal retraction is common in mammals in association with development of a proboscis, and mammals have been studied as extant analogs [e.g., (1, 38)]. Despite retraction of the bony nostril, the fleshy nostril remains rostrally positioned; moreover, some mammals with retracted nasals (e.g., tapirs, elephants) enhance the fundamental amniote rostroventral position by extending the fleshy nostril out on a trunk. Thus, caudal expansion of the bony nostril apparently is not driven by caudal movement of the fleshy nostril, but rather by caudal expansion of the vestibular contents, that is, the narial apparatus.
19. B. G. Bang, *Acta Anat.* **79**, 1 (1971).
20. J. D. K. Dawes, *J. Laryngol. Otol.* **66**, 583 (1952).
21. A. C. Huntley, E. P. Costa, R. D. Rubin, *J. Exp. Biol.* **113**, 447 (1984).
22. R. St. Laurent, J. Larochelle, *J. Exp. Biol.* **194**, 329 (1994).
23. J. A. Ruben, in *Animals and Temperature*, I. A. Johnston, A. F. Bennett, Eds. (Cambridge Univ. Press, New York, 1996), pp. 347–376.
24. K. Schmidt-Nielsen, *Animal Physiology* (Cambridge Univ. Press, New York, ed. 5, 1997).
25. S. Ward et al., *J. Exp. Biol.* **202**, 1589 (1999).
26. Ø. Aas-Hansen, L. P. Folkow, A. S. Blix, *Am. J. Physiol. Regul. Integrat. Comp. Physiol.* **279**, R1190 (2000).
27. J. H. Ostrom, *Bull. Am. Mus. Nat. Hist.* **122**, 33 (1961).
28. C. A. Brochu, *J. Vertebr. Paleontol.* **20**, 1 (2000).
29. A. d'A. Bellairs, *J. Anat.* **83**, 116 (1949).
30. M. E. Malan, *Ann. Univ. Stellenb.* **24A**, 69 (1946).
31. C. W. M. Pratt, *Proc. Zool. Soc. London* **118**, 171 (1948).
32. R. Owen, *Palaeontogr. Soc. Monogr.* **29**, 15 (1875).
33. E. D. Cope, *Am. Nat.* **12**, 71 (1878).
34. O. C. Marsh, *Am. J. Sci.* **26**, 81 (1883).
35. H. F. Osborn, *Bull. Am. Mus. Nat. Hist.* **10**, 219 (1898).
36. O. C. Marsh, *Am. J. Sci.* **27**, 161 (1884).
37. R. T. Bakker, *Nature* **229**, 172 (1971).
38. L. M. Witmer, S. D. Sampson, N. Solounias, *J. Zool. (London)* **249**, 249 (1999).
39. J. B. Hatcher, O. C. Marsh, R. S. Lull, *Monogr. U.S. Geol. Surv.* **49**, 1 (1907).

40. I thank S. W. Cho and J. C. Sedlmayr for assistance with collecting data on the extant sample and S. D. Sampson for his role in the dinosaur studies. The manuscript was improved by comments provided by C. M. Holliday, J. S. McIntosh, P. M. O'Connor, S. D. Sampson, and J. C. Sedlmayr. S. M. Moody, K. de Queiroz, R. M. Eelsey, and J. J. Baumel graciously provided some of the extant specimens. Funding was

provided by NSF grants BSR-9112070 and IBN-9601174 and the Ohio University College of Osteopathic Medicine. The images on the cover and in Fig. 3 were skillfully painted by M. W. Skrepnick and W. L. Parsons, respectively, under the author's direction.

18 May 2001; accepted 27 June 2001

## Methylation of Histone H4 at Arginine 3 Facilitating Transcriptional Activation by Nuclear Hormone Receptor

Hengbin Wang,<sup>1</sup> Zhi-Qing Huang,<sup>2</sup> Li Xia,<sup>1</sup> Qin Feng,<sup>1</sup> Hediye Erdjument-Bromage,<sup>3</sup> Brian D. Strahl,<sup>4</sup> Scott D. Briggs,<sup>4</sup> C. David Allis,<sup>4</sup> Jiemin Wong,<sup>2</sup> Paul Tempst,<sup>3</sup> Yi Zhang<sup>1\*</sup>

Acetylation of core histone tails plays a fundamental role in transcription regulation. In addition to acetylation, other posttranslational modifications, such as phosphorylation and methylation, occur in core histone tails. Here, we report the purification, molecular identification, and functional characterization of a histone H4-specific methyltransferase PRMT1, a protein arginine methyltransferase. PRMT1 specifically methylates arginine 3 (Arg 3) of H4 in vitro and in vivo. Methylation of Arg 3 by PRMT1 facilitates subsequent acetylation of H4 tails by p300. However, acetylation of H4 inhibits its methylation by PRMT1. Most important, a mutation in the S-adenosyl-L-methionine-binding site of PRMT1 substantially crippled its nuclear receptor coactivator activity. Our finding reveals Arg 3 of H4 as a novel methylation site by PRMT1 and indicates that Arg 3 methylation plays an important role in transcriptional regulation.

Covalent modifications of core histone tails play important roles in chromatin function (1). One type of covalent histone modification is methylation (2), which has been observed in diverse organisms from yeast to human (3). However, the consequence of this posttranslational modification is not understood. One major obstacle in understanding the function of histone methylation is the lack of information about the responsible enzymes. The demonstrations that SUV39H1, the human homolog of the *Drosophila* heterochromatic protein Su(var)3-9, is an H3-specific methyltransferase (4) and that methylation of lysine 9 (Lys 9) on histone H3 serves as a binding site for the heterochromatin protein 1 (HP1) (5–7) underscore the impor-

ance of histone lysine methylation in heterochromatin function. Methylation of histones can occur on arginine residues, as well as lysine residues (8). The recent demonstrations that a nuclear receptor coactivator-associated protein, CARM1, is an H3-specific arginine methyltransferase suggests that histone arginine methylation may be involved in transcriptional activation (9).

To identify enzymes involved in core histone methylation, nuclear proteins from HeLa cells were separated into nuclear extract and nuclear pellet followed by further fractionation on DEAE52 and phosphate cellulose P11 columns. Fractions derived as above were assayed for methyltransferase activity by using core histone octamers as substrates (10). Multiple methyltransferase activities with distinctive specificity for histones H3 and H4 were seen (Fig. 1A). By following histone methyltransferase (HMT) activity (Fig. 1A), we purified an H4-specific HMT from the nuclear pellet fraction to homogeneity (11). Analysis of the column fractions derived from the hydroxyapatite column indicated that the peak of the enzymatic activity eluted in fraction 14 and trailed through fraction 26 (Fig. 1B, bottom panel). Silver staining of an SDS-polyacrylamide gel containing the column

<sup>1</sup>Department of Biochemistry and Biophysics, Lineberger Comprehensive Cancer Center, University of North Carolina at Chapel Hill, Chapel Hill, NC 27599–7295, USA. <sup>2</sup>Department of Molecular and Cellular Biology, Baylor College of Medicine, One Baylor Plaza, Houston, TX 77030, USA. <sup>3</sup>Molecular Biology Program, Memorial Sloan Kettering Cancer Center, New York, NY 10021, USA. <sup>4</sup>Department of Biochemistry and Molecular Genetics, University of Virginia Health Science Center, Charlottesville, VA 22908, USA.

\*To whom correspondence should be addressed. E-mail: yi\_zhang@med.unc.edu