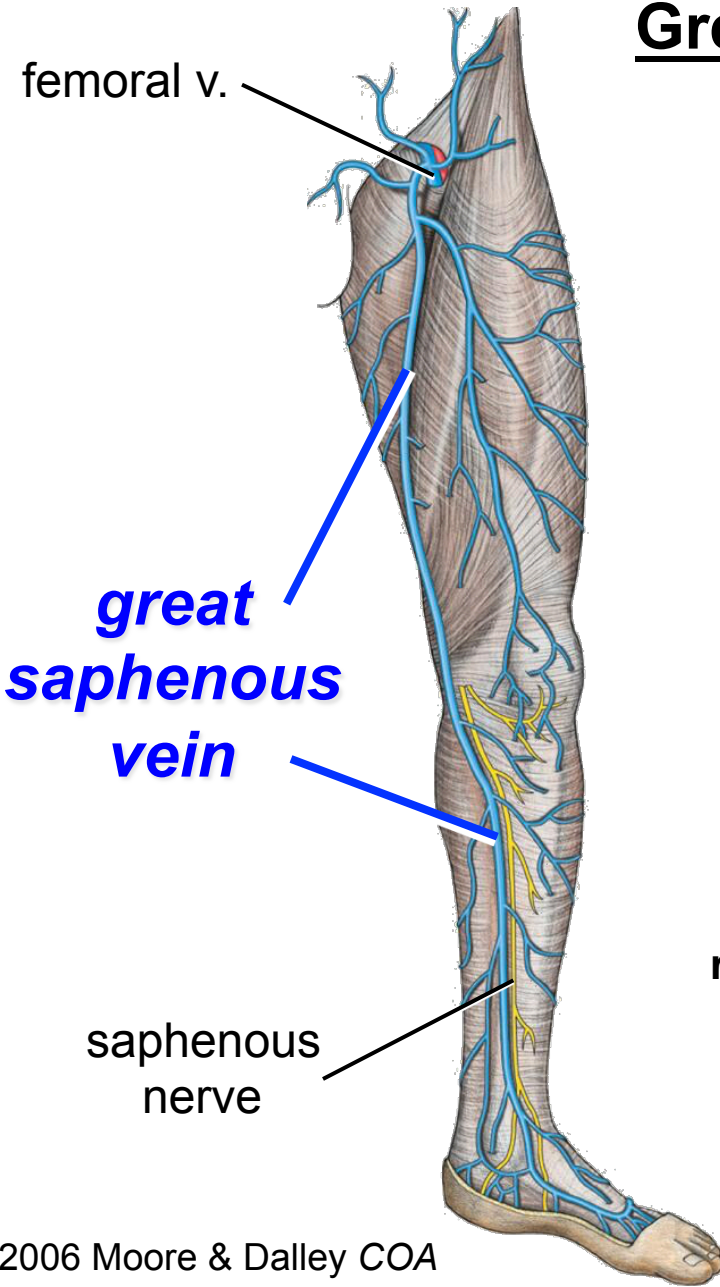
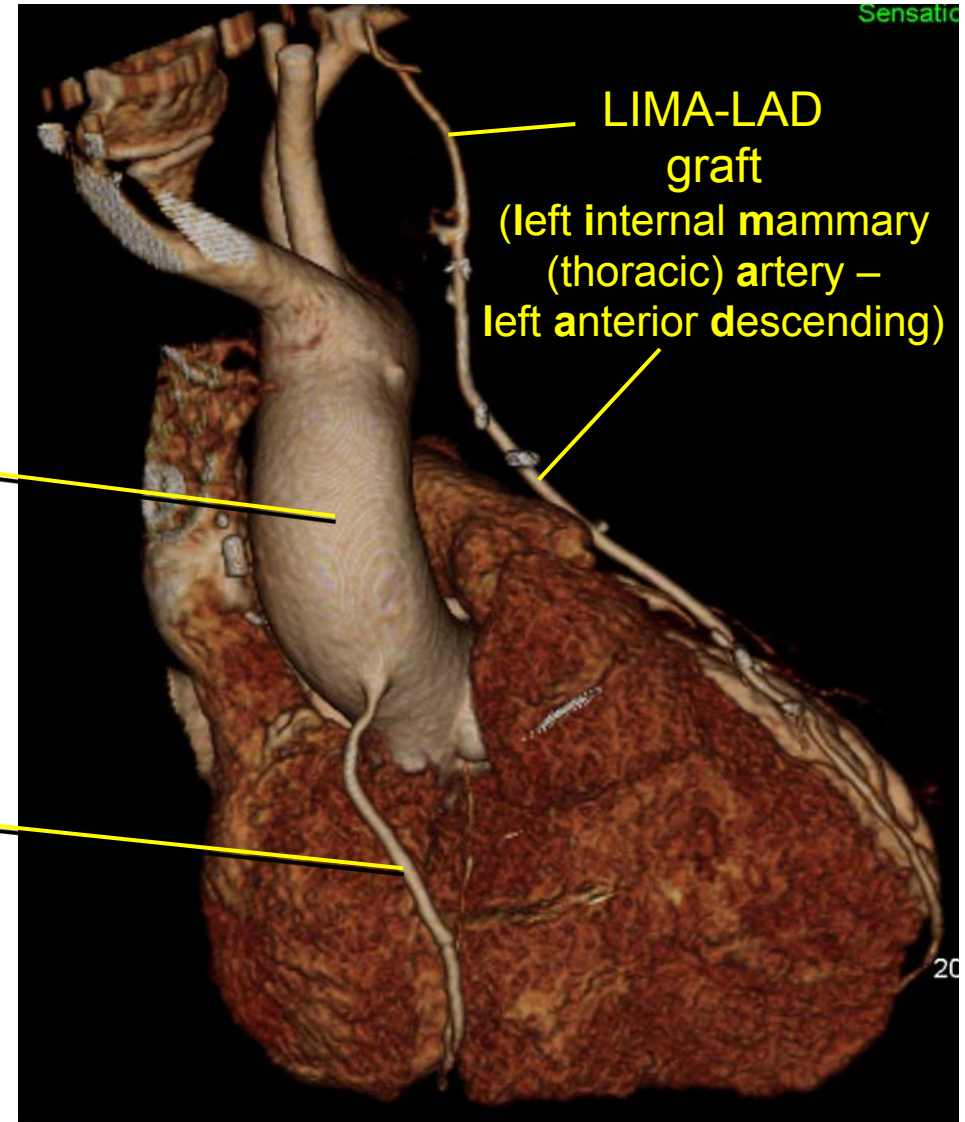


## Great Saphenous Vein Graft



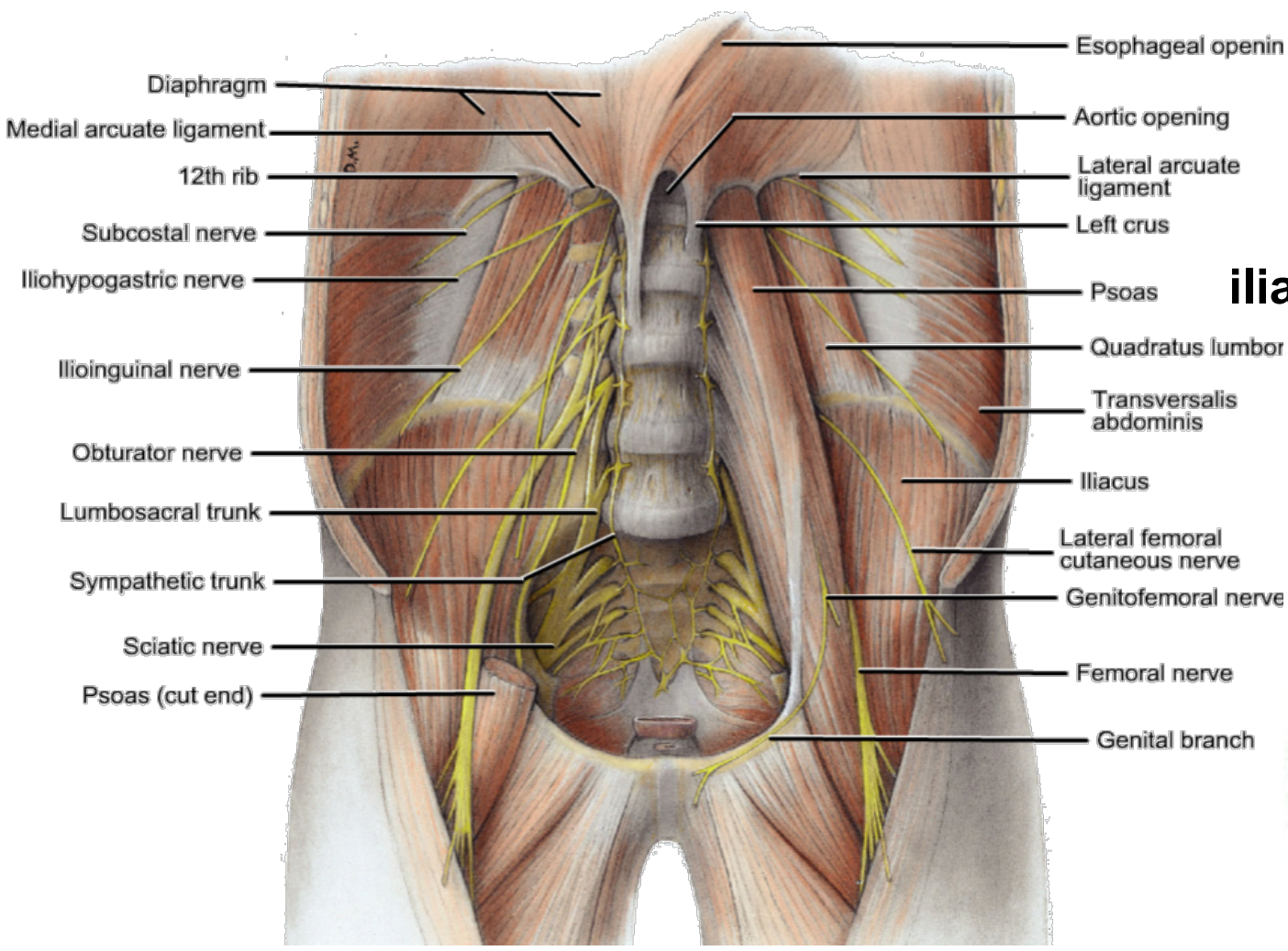
ascending aorta

SVG-RCA graft  
(saphenous vein graft – right coronary artery)

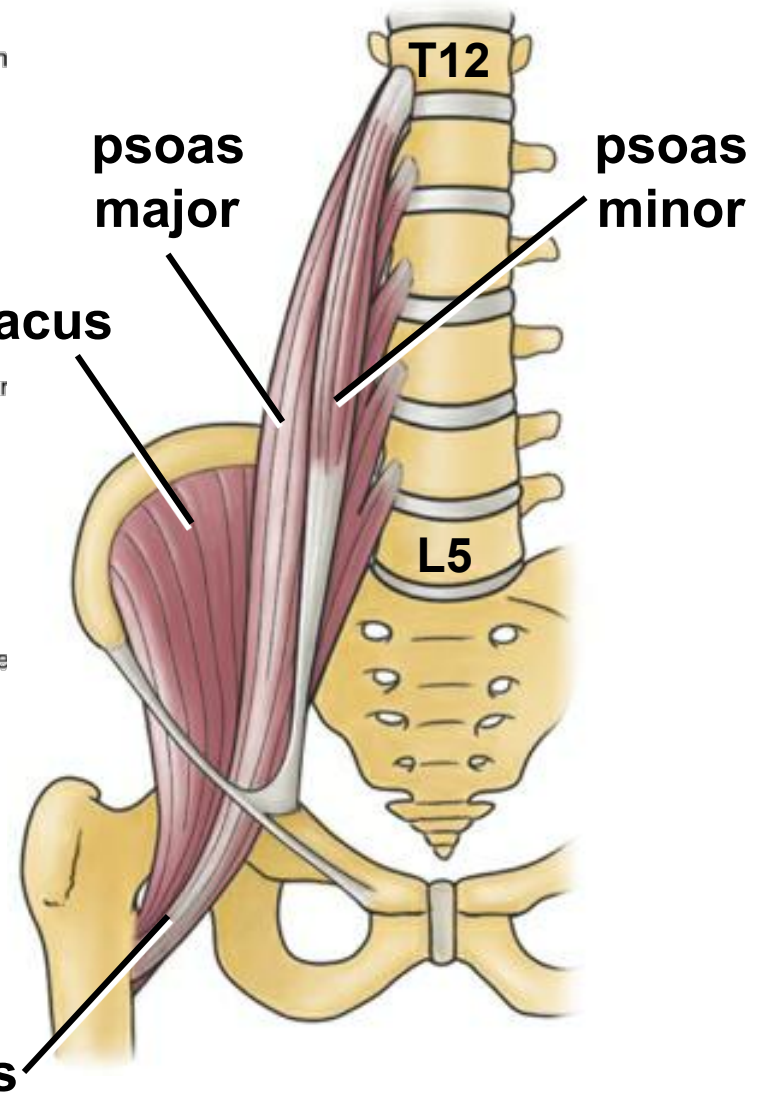


[http://bhavin.typepad.com/.shared/image.html?/photos/uncategorized/fig\\_2\\_79.jpg](http://bhavin.typepad.com/.shared/image.html?/photos/uncategorized/fig_2_79.jpg)

# Psoas Abscess



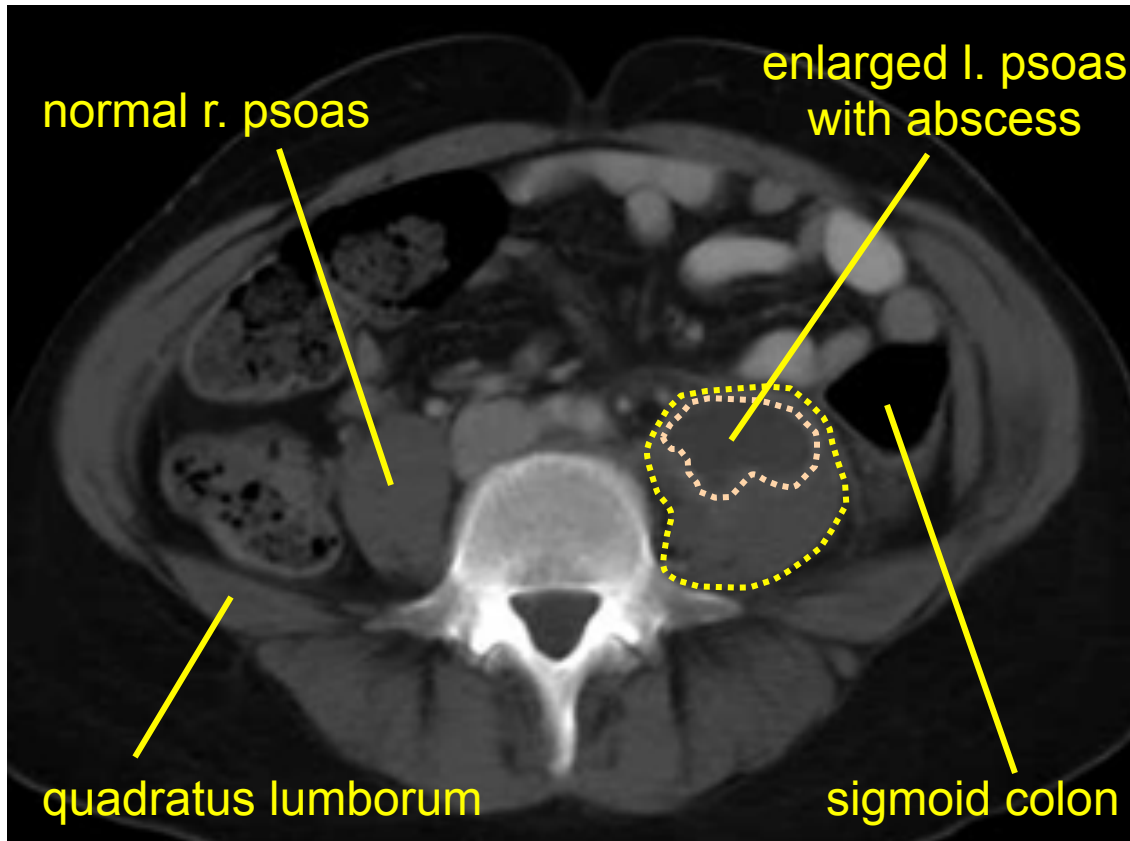
2005 Grant's Atlas



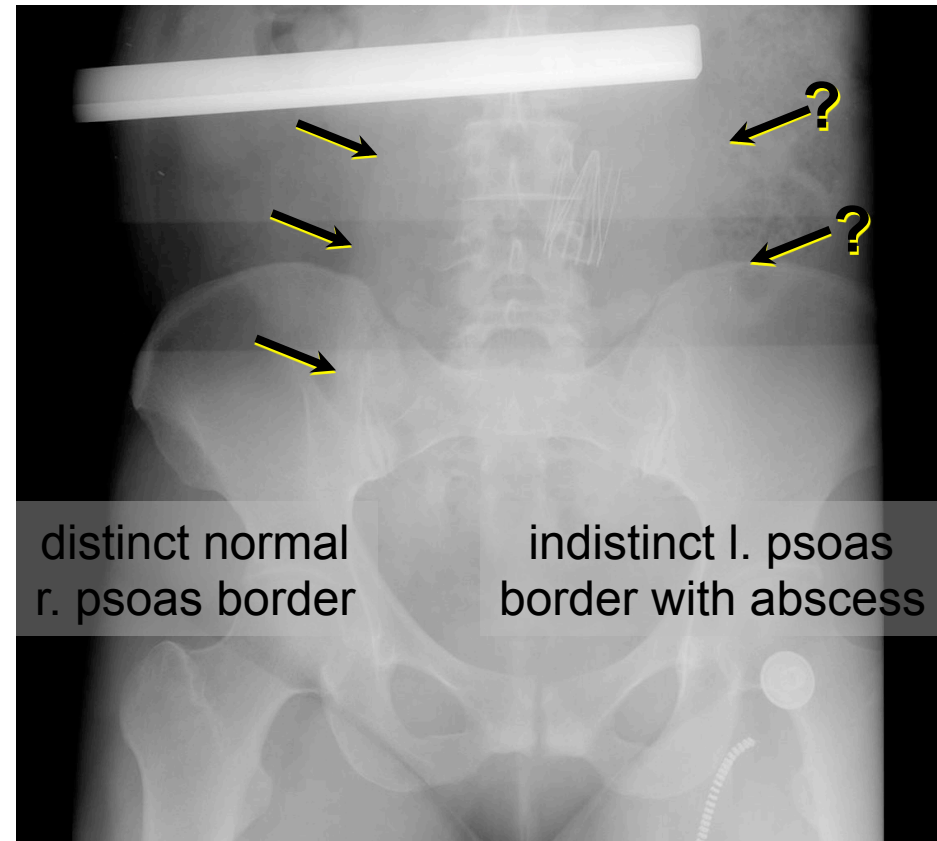
2006 Moore & Dalley COA



## Psoas Abscess

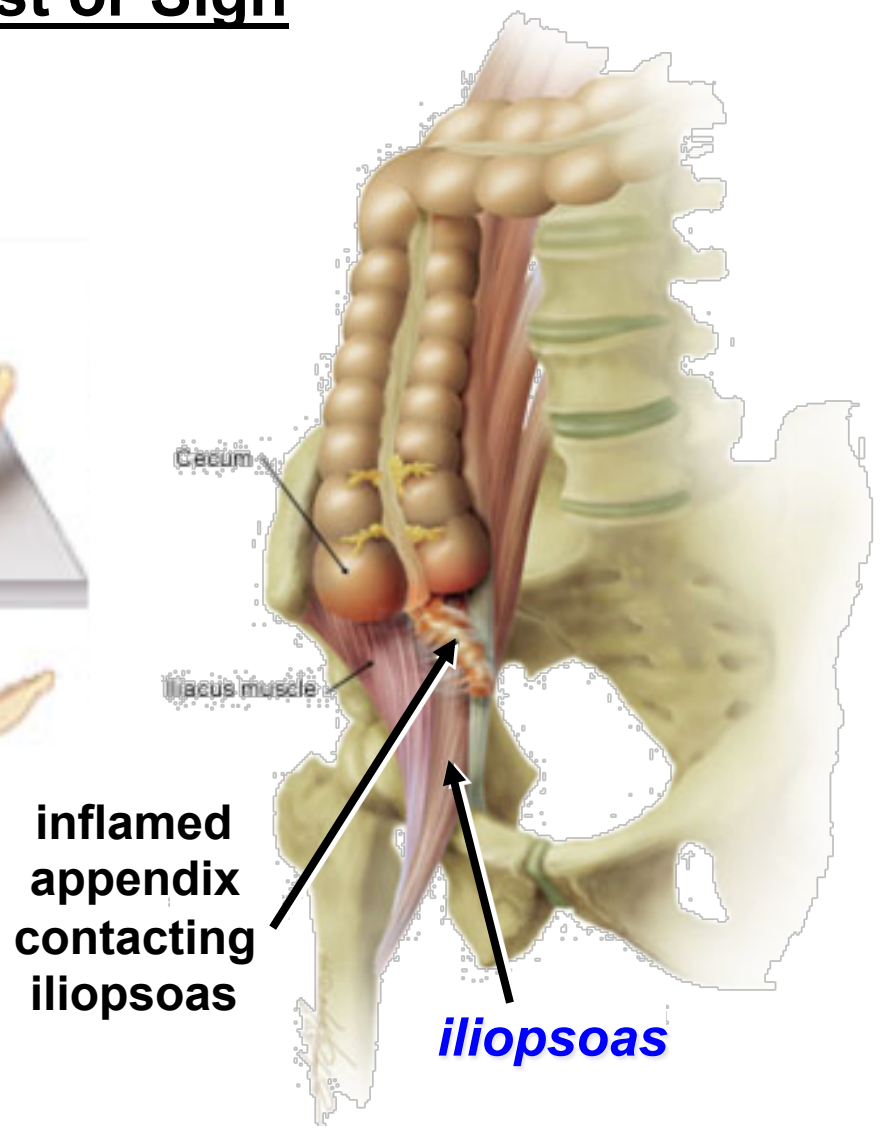
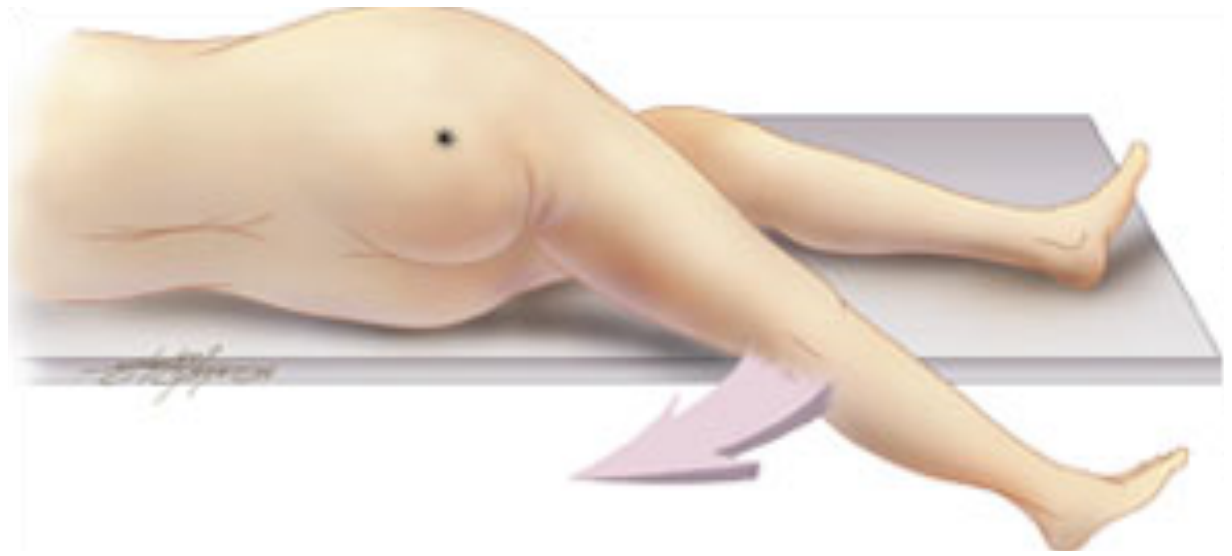

[ispub.com/xml/journals/ijvs/vol6n2/psoas-fig1.jpg](http://ispub.com/xml/journals/ijvs/vol6n2/psoas-fig1.jpg)

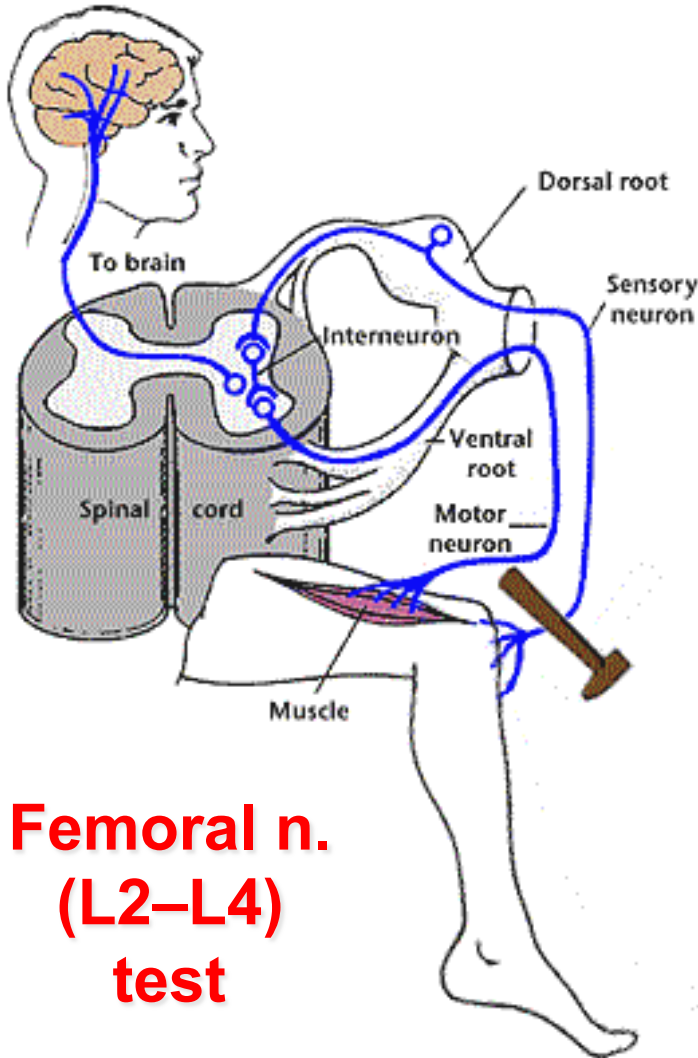


[rad.usuhs.mil/medpix/tachy\\_pics/thumb/synpic20917.jpg](http://rad.usuhs.mil/medpix/tachy_pics/thumb/synpic20917.jpg)

## (Ilio-) Psoas Test or Sign



# Knee Jerk (Patellar) Reflex



**Femoral n.  
(L2-L4)  
test**

