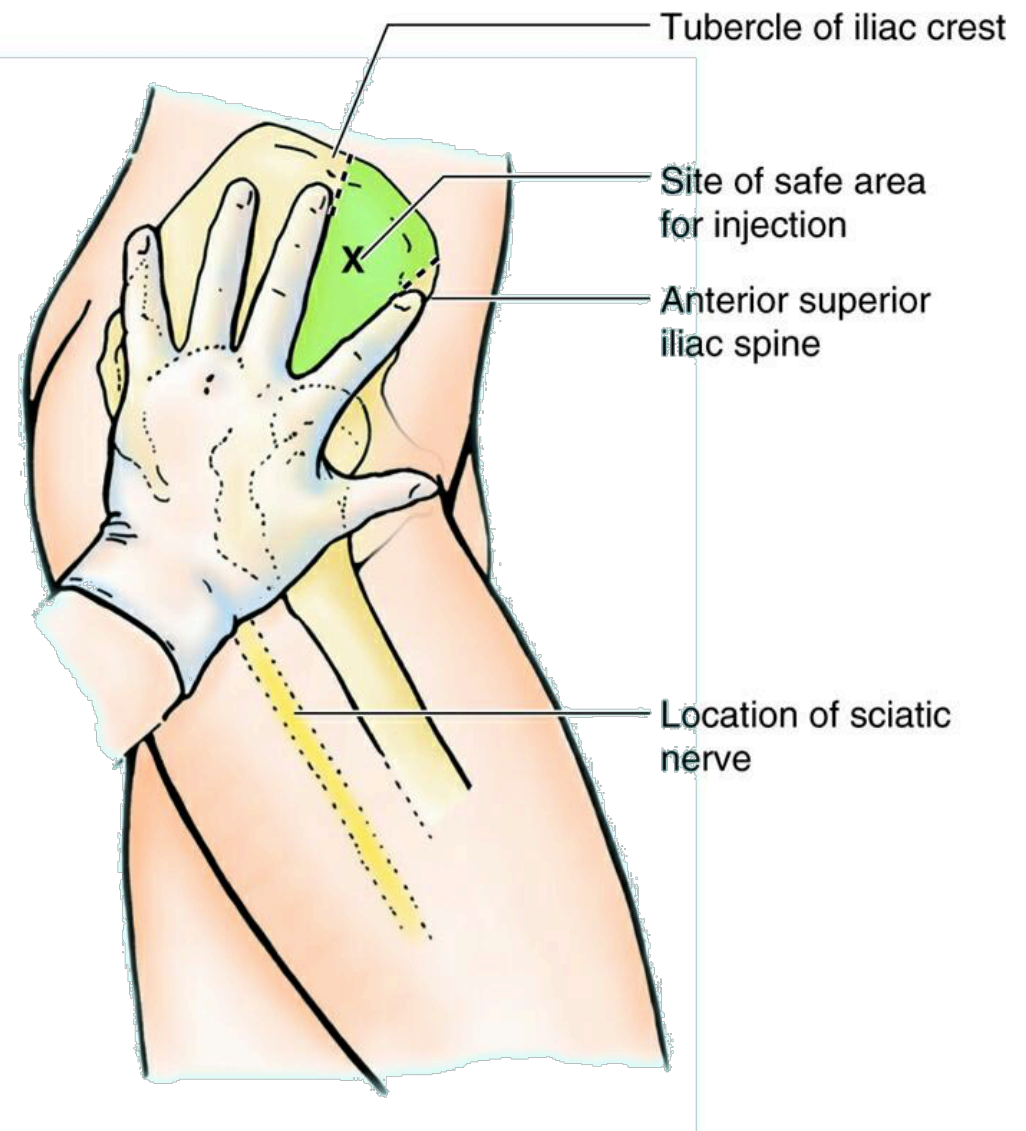
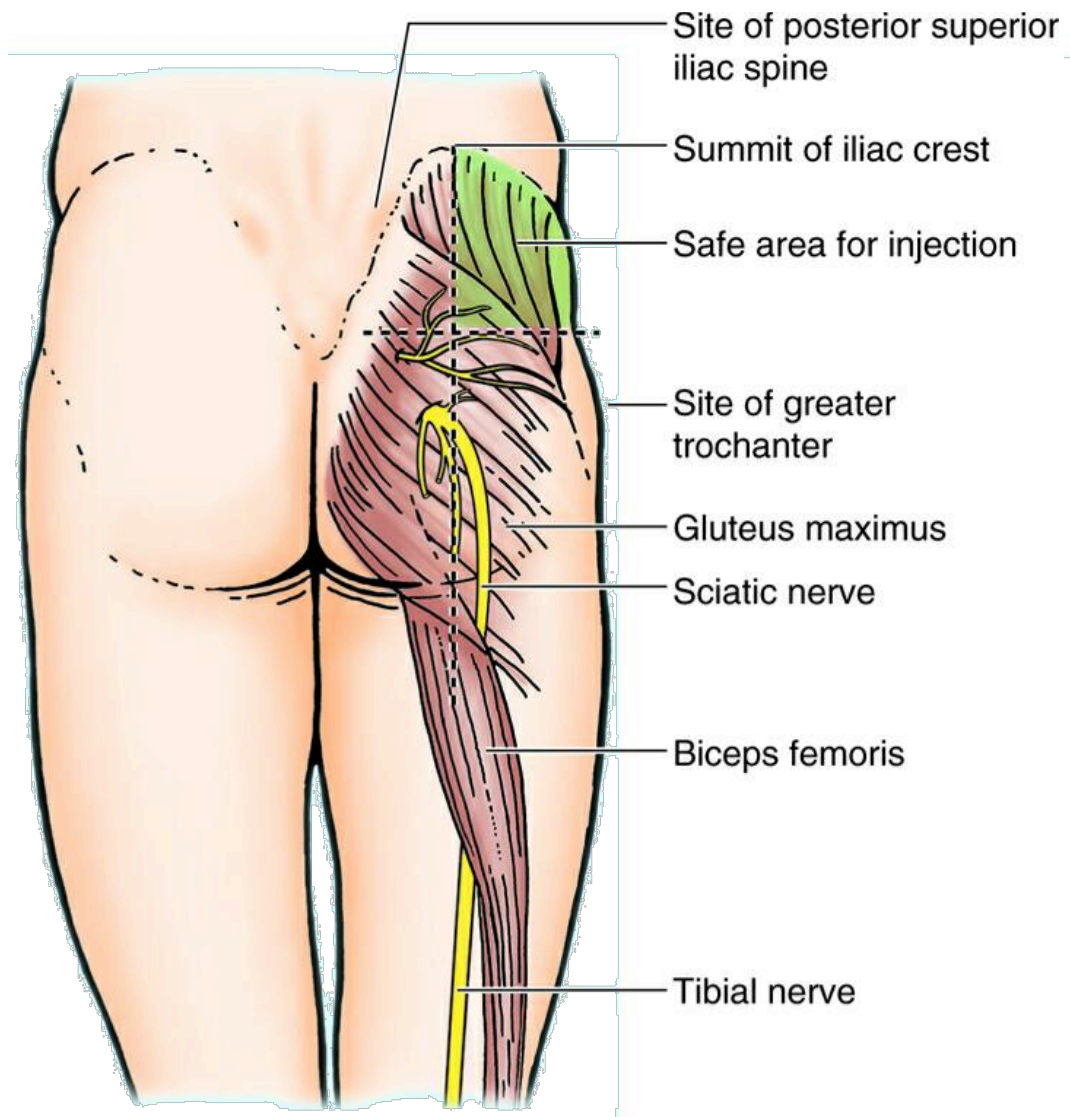
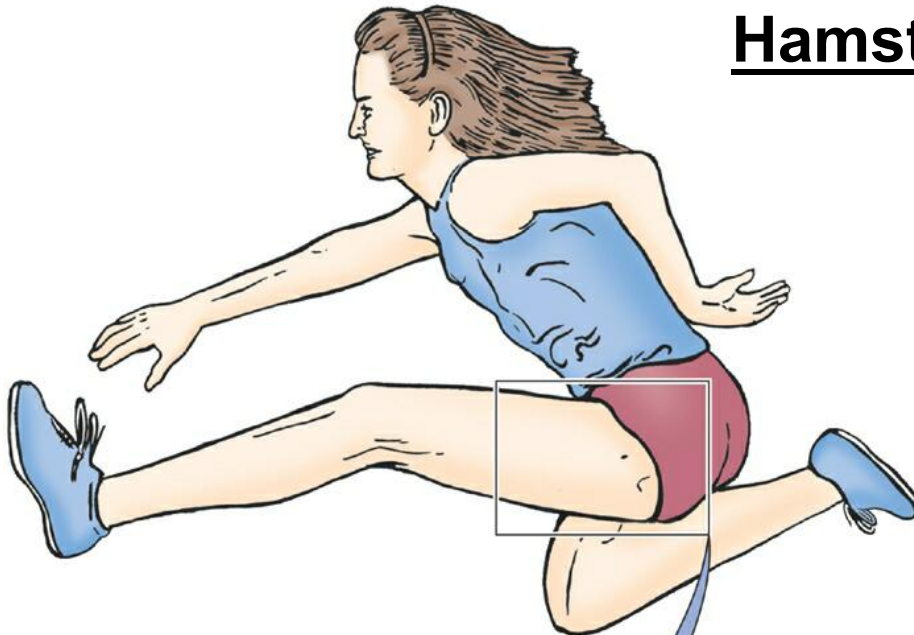


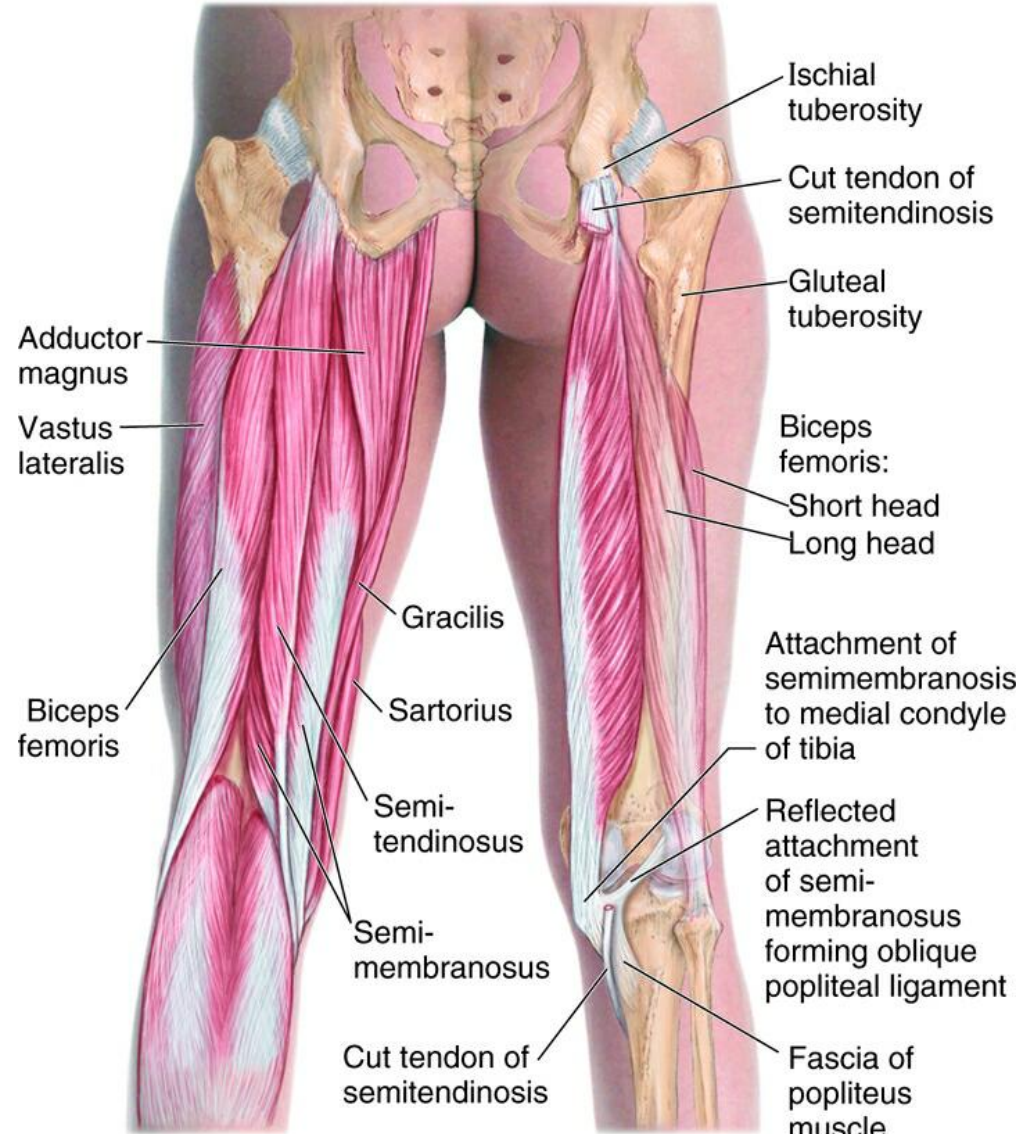
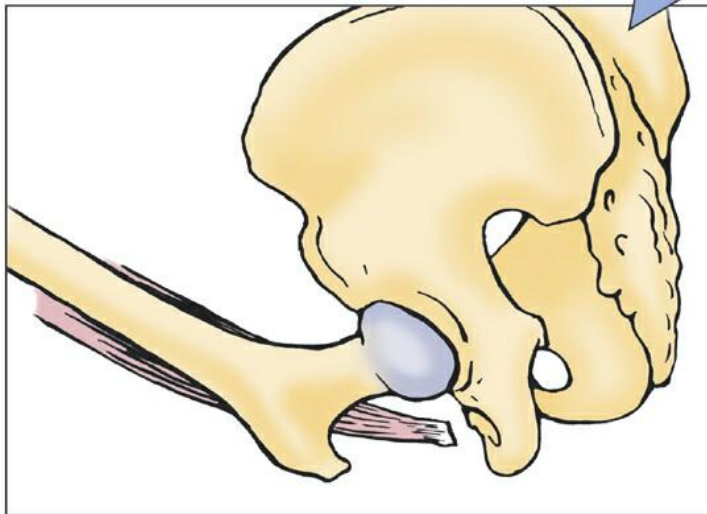
Gluteal Intramuscular Injection



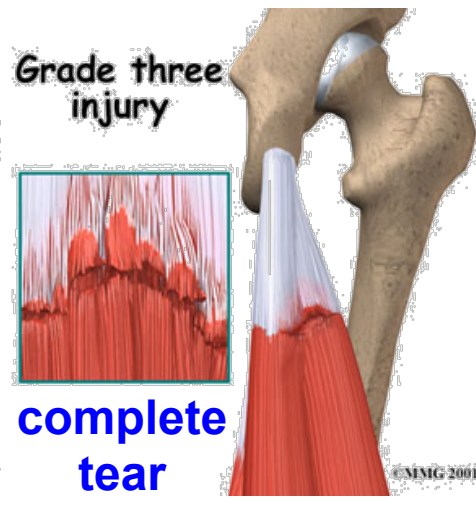
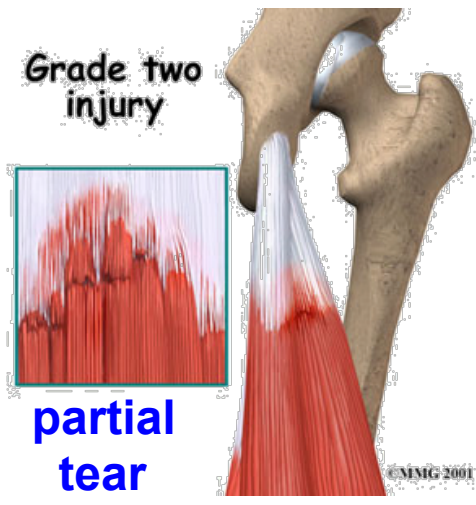
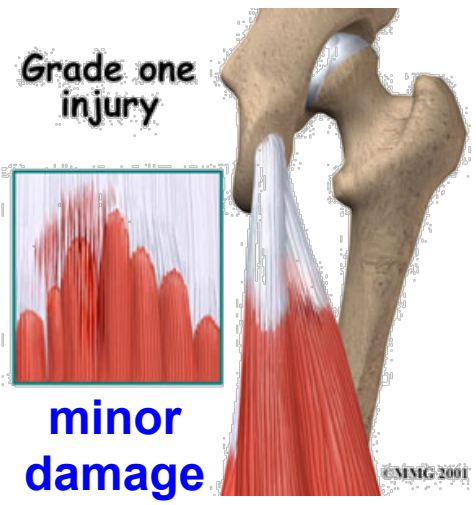
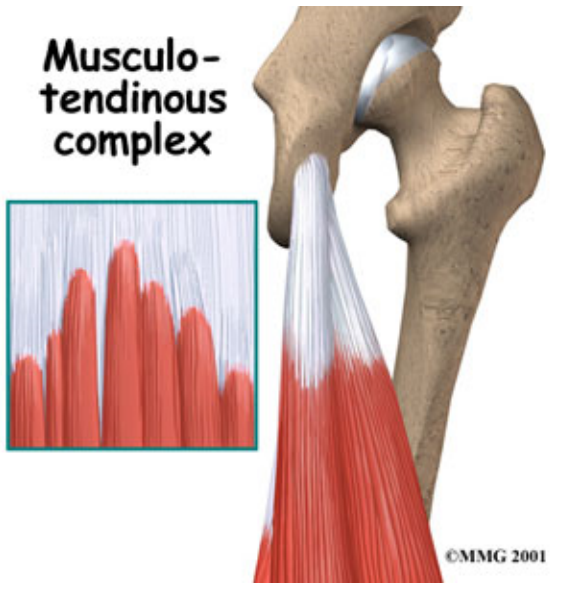
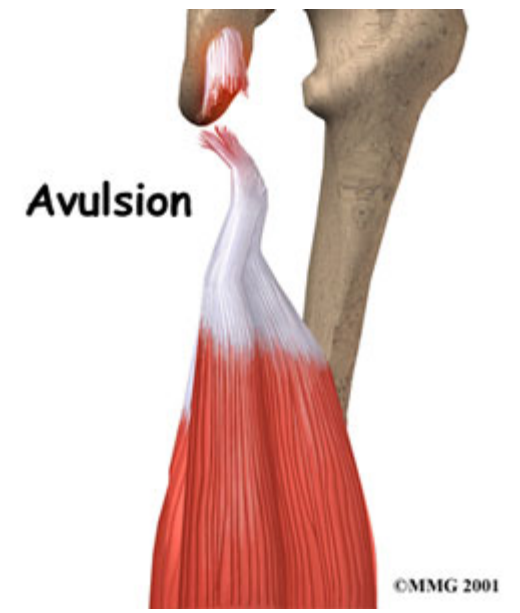
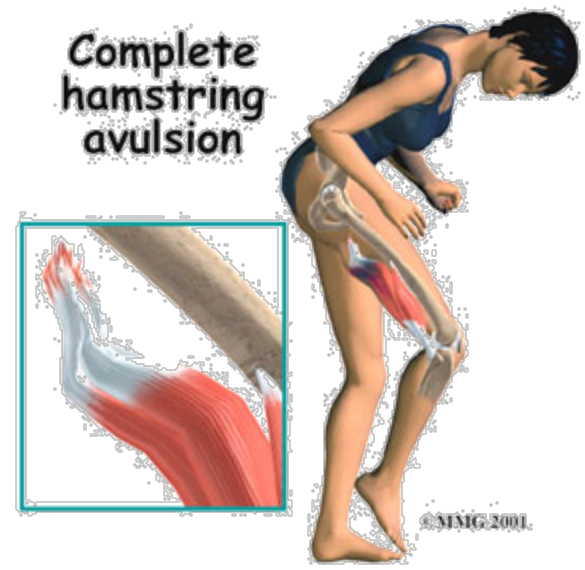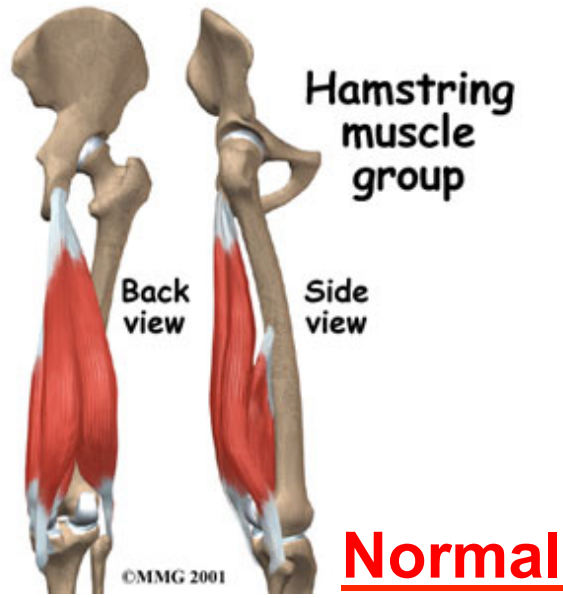
Hamstring Pull



avulsion of hamstring



Hamstring Pull



Superior Gluteal N. Palsy (Positive Trendelenburg Sign)

